

External Quality Assessment Scheme

## Preanalytics and process in anatomic pathology, assessment 2, 2022

### Specimens

This assessment consists of the three case reports which are described at the end of this letter. This assessment is based on the preanalytics and process errors which typically observed in pathology laboratory. Cases are presented also on the LabScala e-form.

### Result reporting

Please enter the results via LabScala ([www.labskala.com](http://www.labskala.com)).

We ask you to identify preanalytical or laboratory process errors and define your possible actions. You can choose more than one answer. If you do not find your answer from the drop-down menu, please describe your action and/or the preanalytical error in the free text Comment field (in English please).

With one order you may return five results per case (5 results x 5 cases). In order to separate multiple results, give a respondent name in the field in question and you will receive a respondent specific result table for each of the results sent. If you want to send more than one result per case, press "Add response +" on the blue column, and new set of questions opens.

### Case 1

The pathologists who interpreted gastroscopy specimens found that the tissue morphology of the biopsies from a certain department was partially impaired, and the interpretation of slides was also challenging by uneven staining. The interpretation was uncertain, and several samples required consultation and second opinions. Some pathologists asked to adjust stainings.

There was no mention of a deviation from laboratory processes in the laboratory information system. Only the quality manager of the laboratory commented on the increased number of lost biopsy samples. However, department had introduced new safety formalin containers that minimize exposure to formalin a few months ago.

What could be the reason for the weakened morphology and abnormal staining results? What could be the error in the laboratory process?

### Case 2

To make the process more efficient, the laboratory transferred a few special stains, such as GIEMSA and Congo red stains, from the fully automated special staining instrument to the high-capacity Sakura Prisma "Dipp and Dunk" type staining platform.

The protocols were designed to be as identical as possible in both instruments. The results of both staining platforms were compared in the validation processes. A quite similar staining result was obtained with both staining platforms. The stainings were optimized for digital pathology imaging and the results were interpreted utilizing the scanned whole slide images (WSI). Special attention was considering to the dehydration steps of the protocol. Remaining water deposits in slides on the last external quality assessment have been decreased results of current run.

2022-11-29

### INSTRUCTIONS

Product no. 7806  
LQ779922021-023/ FI

---

The results should be reported no later than **December 22, 2022.**

---

### Inquiries

EQA Coordinator  
Pia Eloranta  
[pia.eloranta@labquality.fi](mailto:pia.eloranta@labquality.fi)

### Labquality Oy

Kumpulantie 15  
FI-00520 HELSINKI  
Finland

Tel. + 358 9 8566 8200  
Fax + 358 9 8566 8280

[info@labquality.fi](mailto:info@labquality.fi)  
[www.labquality.fi](http://www.labquality.fi)



The quality and quantity of the control tissues was sufficient for the validation. For Congo red, high quality and wrinkle-free sections were microtomed using 4 µm thickness set up. Validation was performed with fresh staining solutions for one day. The device did not have diagnostic specimen glasses during validation process.

The essential validation documentation was done on time and the staff was informed about the changes. Post-validation monitoring of the device and staining quality was not actually done, because process audit of the routine and special histology stainings had been done about a month before the validation with no deviations.

The staining process was the bottle neck of the laboratory process after validation and number of the restained slides increased significantly. However, some of the pathologists criticized the staining quality and some thought the staining quality were excellent.

Although a comparable staining result was obtained in the validation, has something possibly gone wrong and why has the number of repeated stainings increased?

### Case 3

After the conference related to skin and melanoma diagnostics, the laboratory decided to validate the new Melan A (MART1) antibody for immunohistochemistry and found that the new rabbit monoclonal Melan A (e.g. EP43) antibody and the mouse monoclonal BS52 antibody are clearly more sensitive than previously used mouse Melan A (A103) monoclonal antibody for melanoma cases.

Several melanoma sections and normal benign skin sections were used as validation material. Skin and melanoma cases contained Melan A expression level from weak to very strong respectively. The validation was properly documented, and the A103 clone was changed to the BS52 clone due to its better sensitivity in melanoma diagnostic in Ventana Ultra platform.

Later it turned out that the results were exceptionally weak in the diagnosis of adrenal and ovarian carcinoma, and even completely negative results were surprising.

Ventana's Benchmark Ultra staining platform was used.

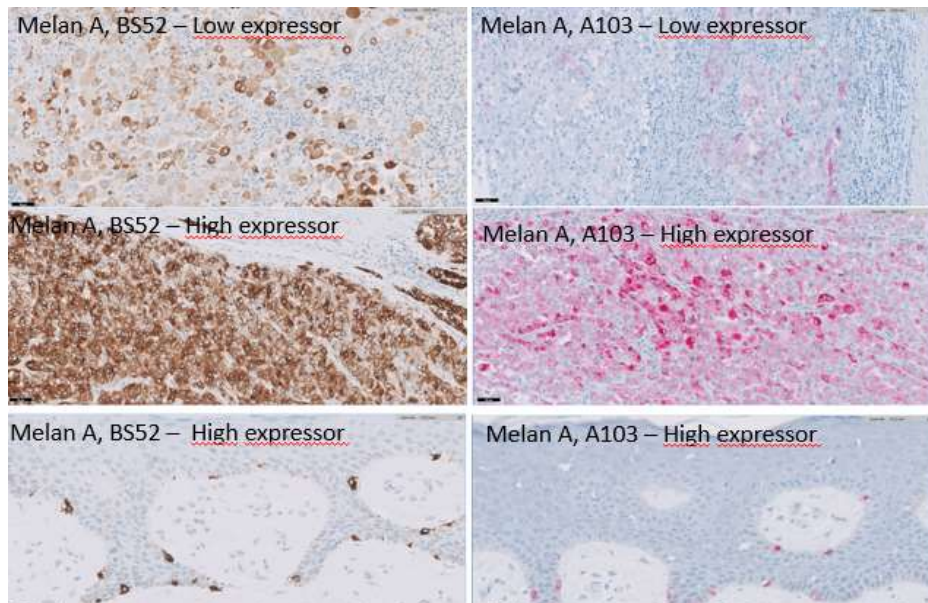


Figure 1: Comparison of the different Melan A clones using melanoma and skin sections.

## Questions

### What laboratory process error is present?

Confusion with different antibody clones of IHC  
Deviation in request form  
Errors during sample handling, storage and delivery  
Extraneous tissue, contamination  
Fixation error, under fixation, inappropriate volume of fixative  
Inappropriate validation process  
Incomplete sections /sections from the wrong layer  
Lost specimen, tissue lost in processing  
Missing sample  
Normal result, no laboratory errors/deviations  
Number of containers/samples do not match  
Number of sections per block insufficient  
Number of slides insufficient  
Poor morphology, autolysis  
Poor quality decalcification  
Poor quality staining  
Poor tissue processing  
Sample acceptance criteria are not met  
Sample inappropriate  
Wrong block  
Wrong labelling or inappropriate sample identifiers

### What are the implications on this case?

Could affect for therapeutic decision  
Delay in sample processing  
Dissatisfaction of client  
Incorrect result  
Interpretation difficulties  
Need for re-biopsy  
Need for re-grossing  
Need for re-sections, extra slides or analyses  
No diagnosis  
No result  
None  
Potential Litigation  
Risk for patient safety  
Sample rejected from the laboratory process  
Wrong diagnosis  
Wrong staging

### What can be the reasons behind this type of errors?

Archive error  
Cassette code error  
Cut-up /Grossing errors  
Deviations in embedding, wrong orientation, wrong level  
Deviations in microtomy  
Error in validation design or implementation  
Errors in operating room  
Grossing errors  
Inadequate internal quality management  
Inappropriate sampling technique  
Incorrect IT labelling  
Information system error  
Microscopy error  
No errors  
No request form, or incorrectly completed request form received  
Original diagnosis is wrong  
Pathologist error  
Poor cytology technique  
Poor fixation of the specimen  
Possible error in the standard operating procedure  
Sample confusion  
Sample inappropriate  
Specimen not checked for tumour content  
Tumour content or type not associated with analysis  
Wrong specimen

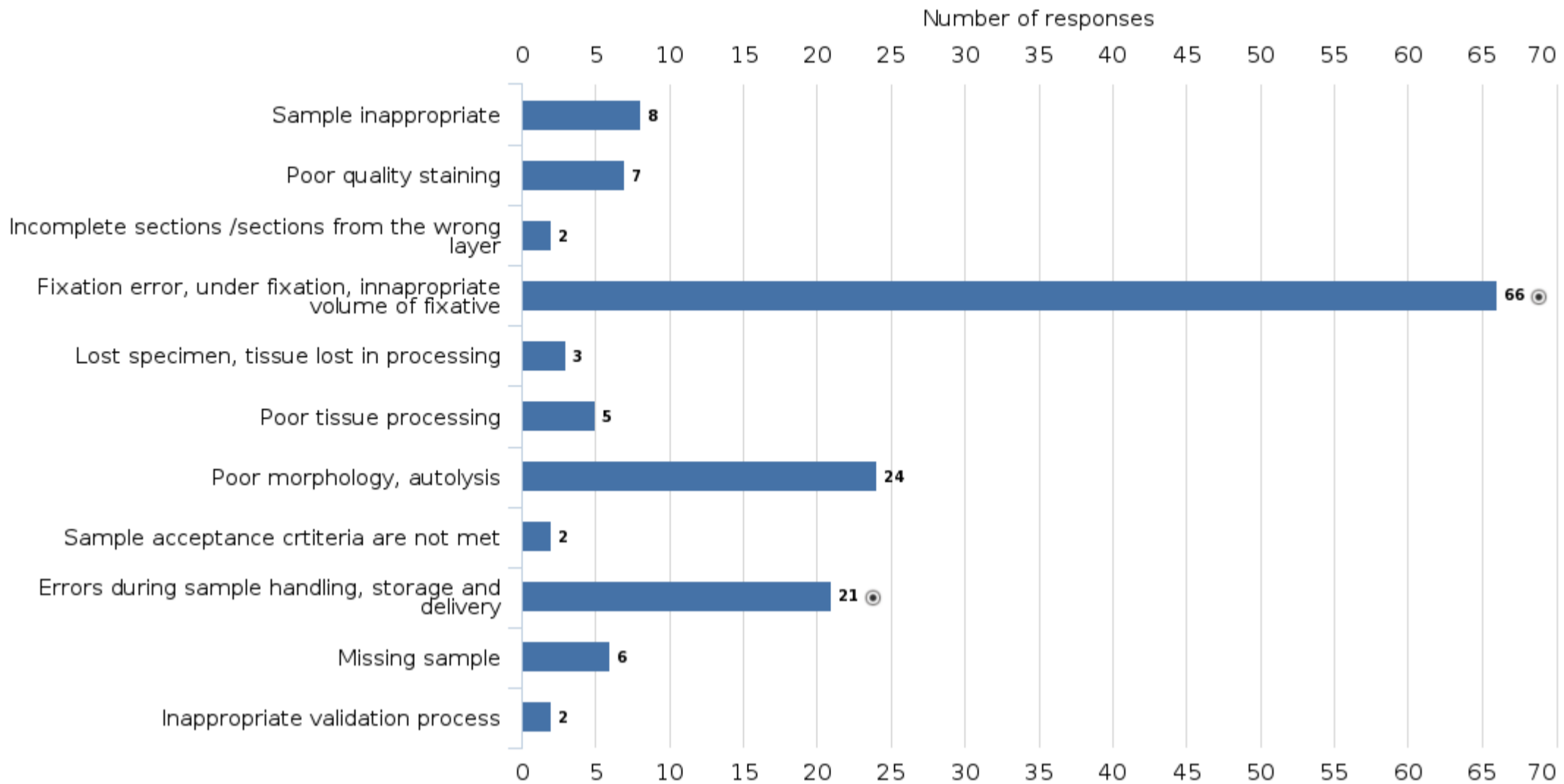
**Case 1**

The pathologists who interpreted gastroscopy specimens found that the tissue morphology of the biopsies from a certain department was partially impaired, and the interpretation of slides was also challenging by uneven staining. The interpretation was uncertain, and several samples required consultation and second opinions. Some pathologists asked to adjust stainings.

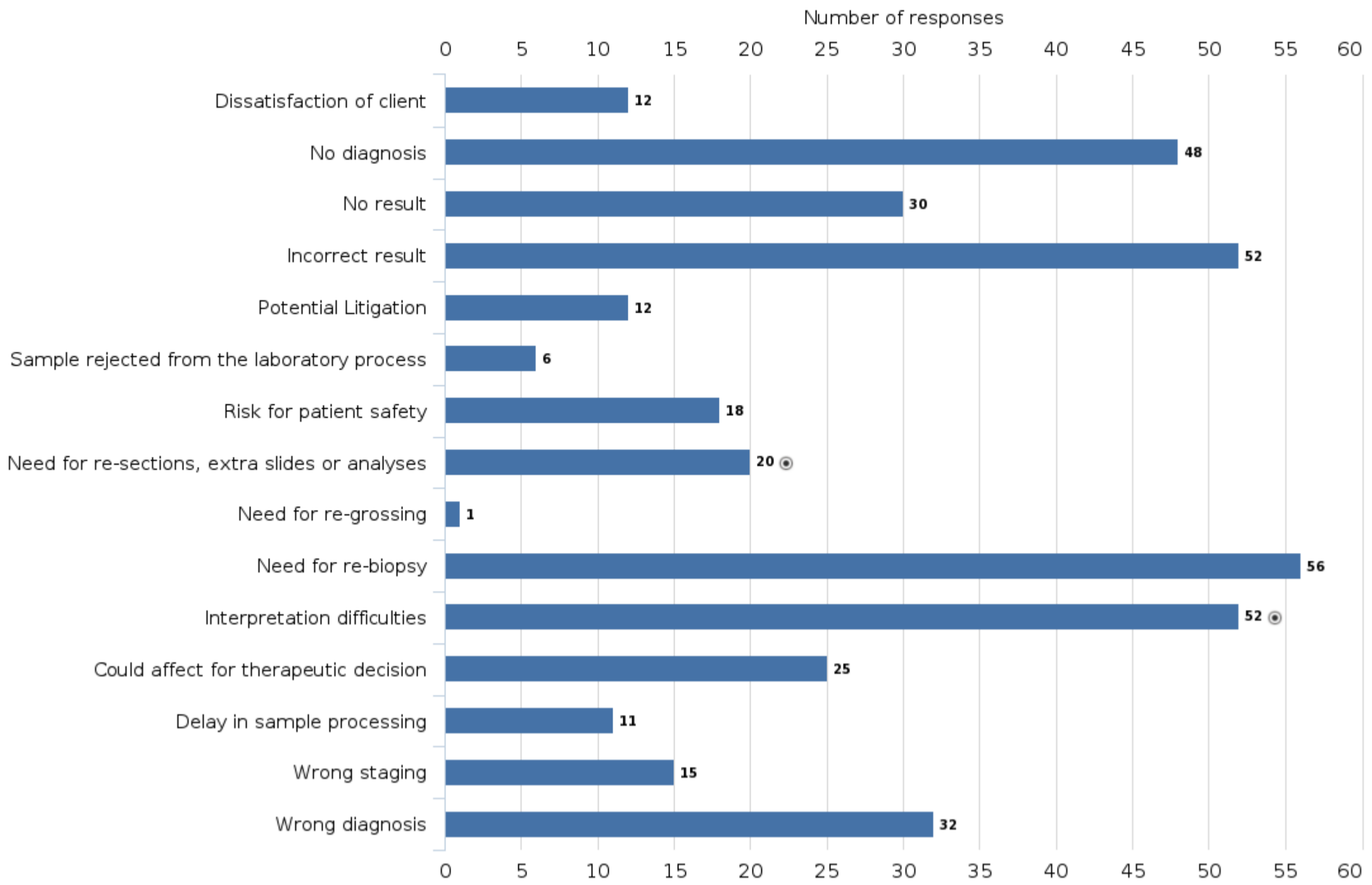
There was no mention of a deviation from laboratory processes in the laboratory information system. Only the quality manager of the laboratory commented on the increased number of lost biopsy samples. However, department had introduced new safety formalin containers that minimize exposure to formalin a few months ago.

What could be the reason for the weakened morphology and abnormal staining results? What could be the error in the laboratory process?

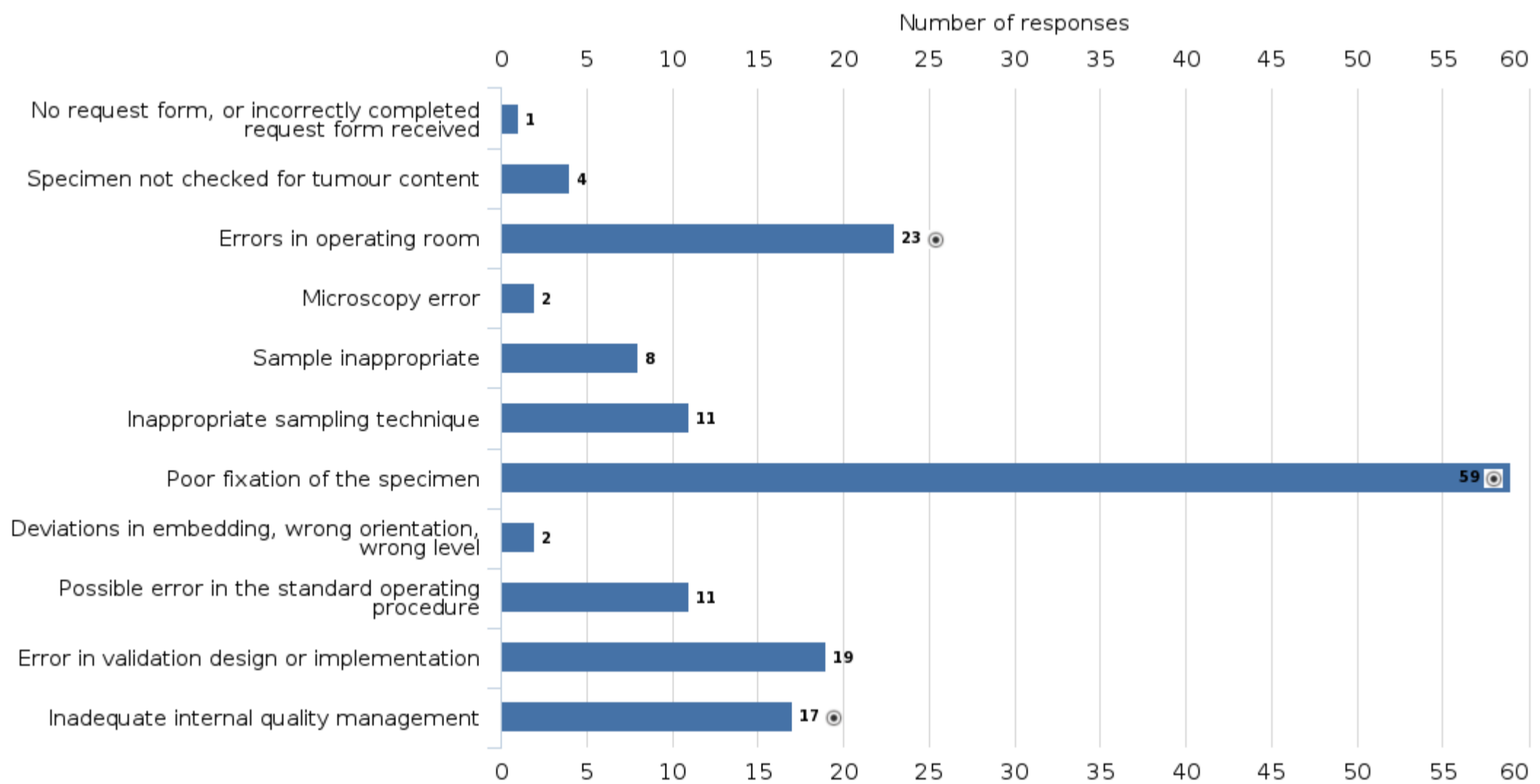
**What laboratory process error is present?**



What are the implications on this case?



What can be the reasons behind this type of errors?



**Case 2**

To make the process more efficient, the laboratory transferred a few special stains, such as GIEMSA and Congo red stains, from the fully automated special staining instrument to the high-capacity Sakura Prisma "Dipp and Dunk" type staining platform.

The protocols were designed to be as identical as possible in both instruments. The results of both staining platforms were compared in the validation processes. A quite similar staining result was obtained with both staining platforms. The stainings were optimized for digital pathology imaging and the results were interpreted utilizing the scanned whole slide images (WSI). Special attention was considering to the dehydration steps of the protocol. Remaining water deposits in slides on the last external quality assessment have been decreased results of current run.

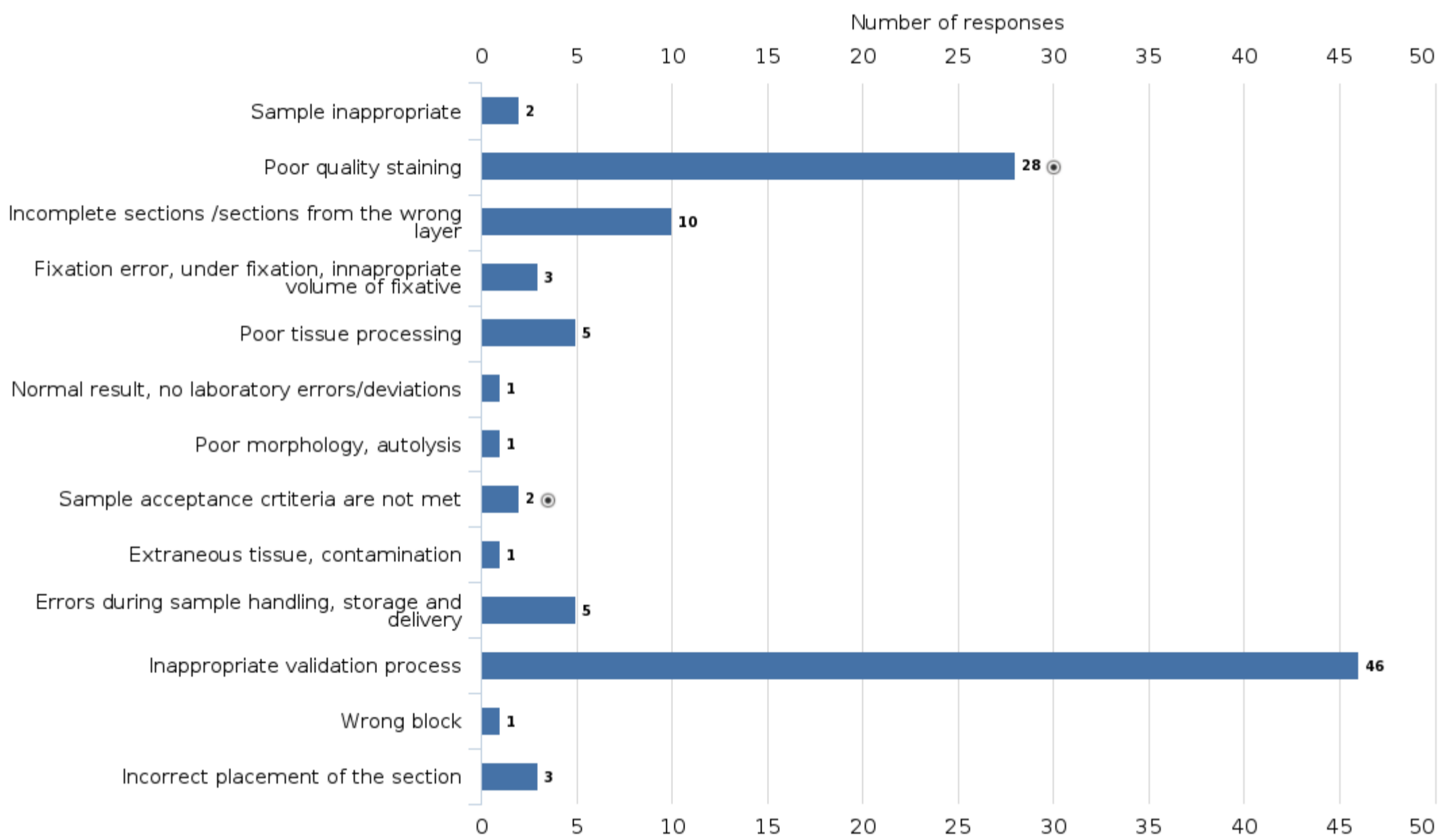
The quality and quantity of the control tissues was sufficient for the validation. For Congo red, high quality and wrinkle-free sections were microtomed using 4 µm thickness set up. Validation was performed with fresh staining solutions for one day. The device did not have diagnostic specimen glasses during validation process.

The essential validation documentation was done on time and the staff was informed about the changes. Post-validation monitoring of the device and staining quality was not actually done, because process audit of the routine and special histology stainings had been done about a month before the validation with no deviations.

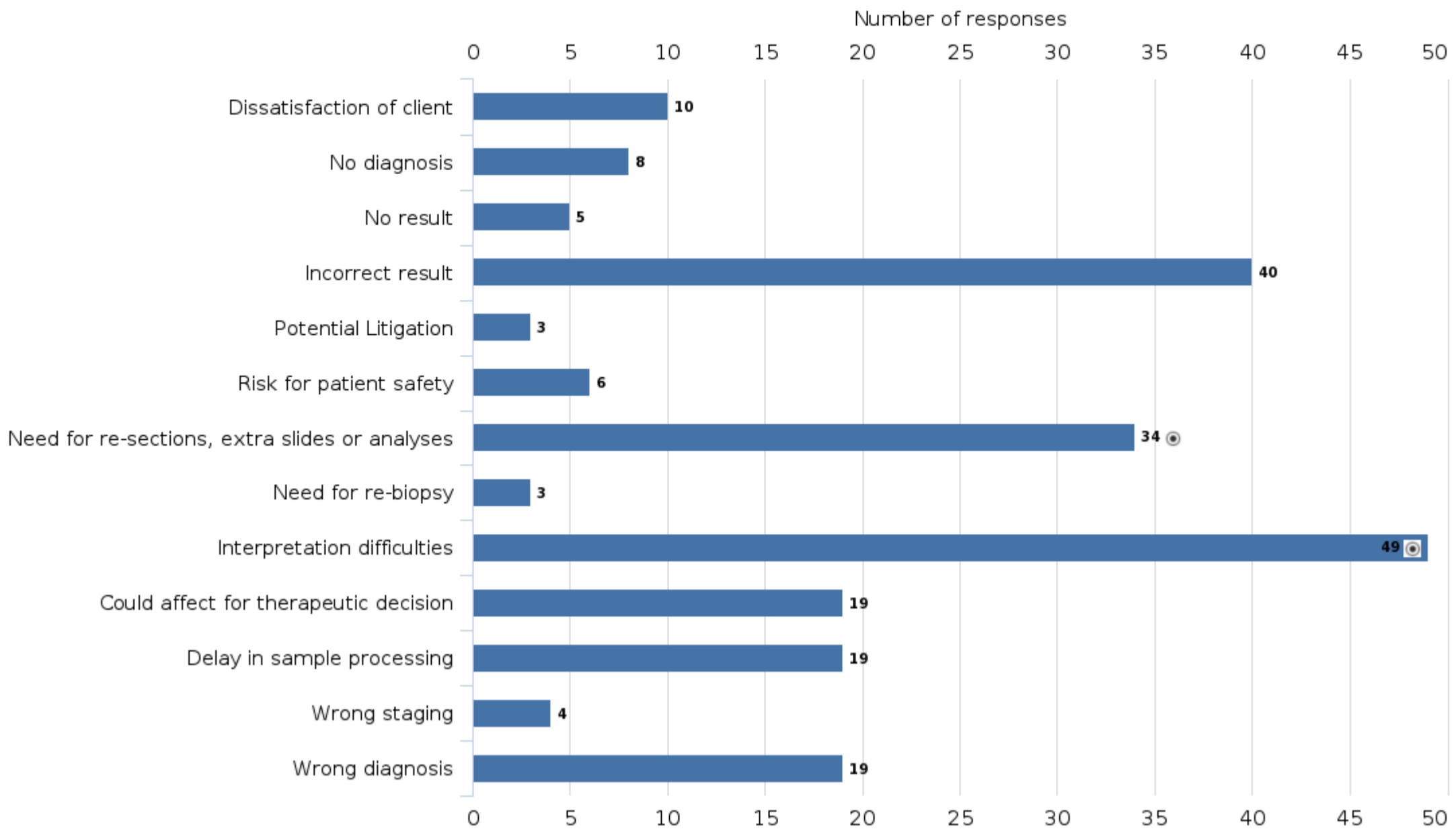
The staining process was the bottle neck of the laboratory process after validation and number of the restained slides increased significantly. However, some of the pathologists criticized the staining quality and some thought the staining quality were excellent.

Although a comparable staining result was obtained in the validation, has something possibly gone wrong and why has the number of repeated stainings increased?

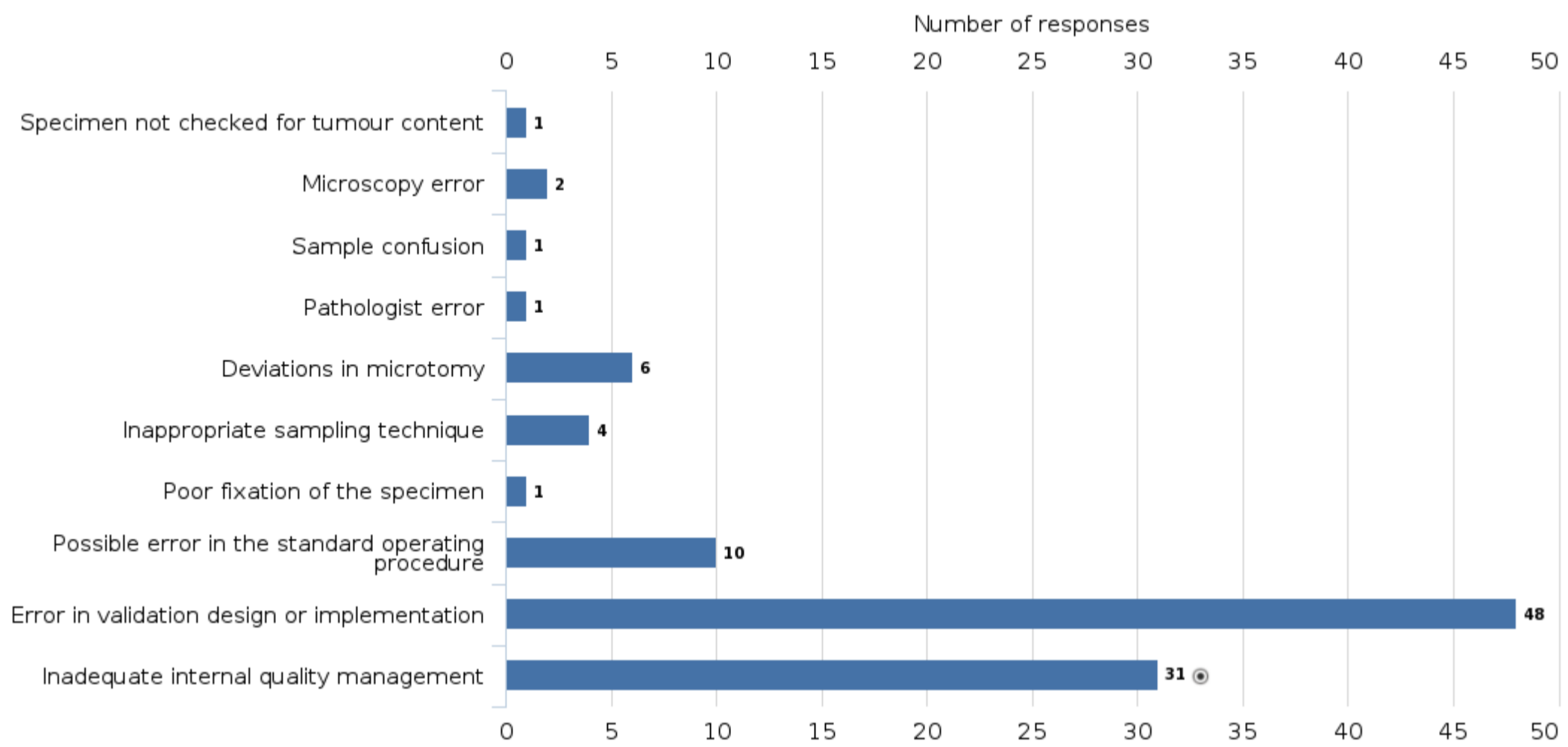
**What laboratory process error is present?**



What are the implications on this case?



What can be the reasons behind this type of errors?



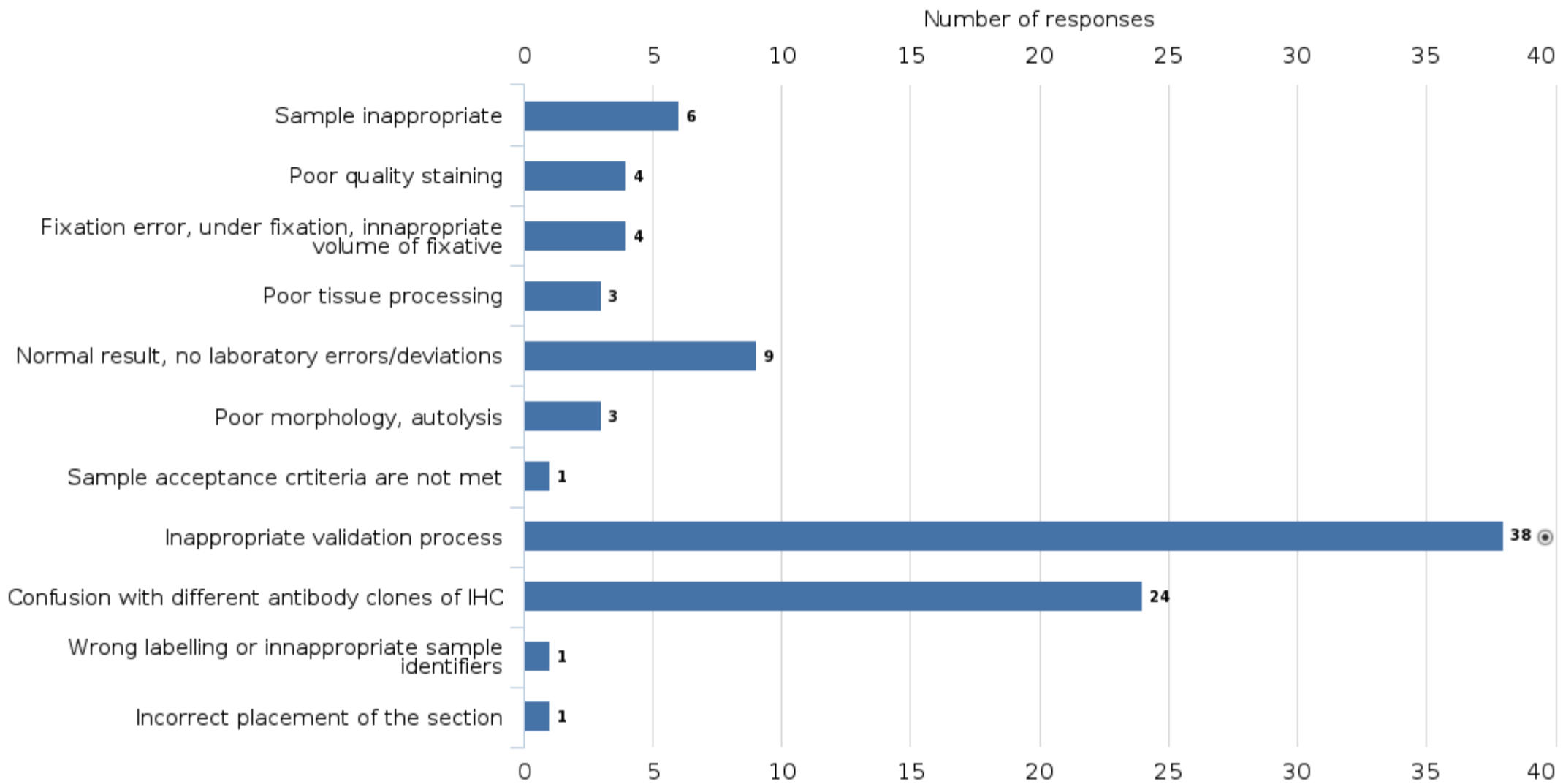
**Case 3**

After the conference related to skin and melanoma diagnostics, the laboratory decided to validate the new Melan A (MART1) antibody for immunohistochemistry and found that the new rabbit monoclonal Melan A (e.g. EP43) antibody and the mouse monoclonal BS52 antibody are clearly more sensitive than previously used mouse Melan A (A103) monoclonal antibody for melanoma cases.

Several melanoma sections and normal benign skin sections were used as validation material. Skin and melanoma cases contained Melan A expression level from weak to very strong respectively. The validation was properly documented, and the A103 clone was changed to the BS52 clone due to its better sensitivity in melanoma diagnostic in Ventana Ultra platform. Later it turned out that the results were exceptionally weak in the diagnosis of adrenal and ovarian carcinoma, and even completely negative results were surprising.

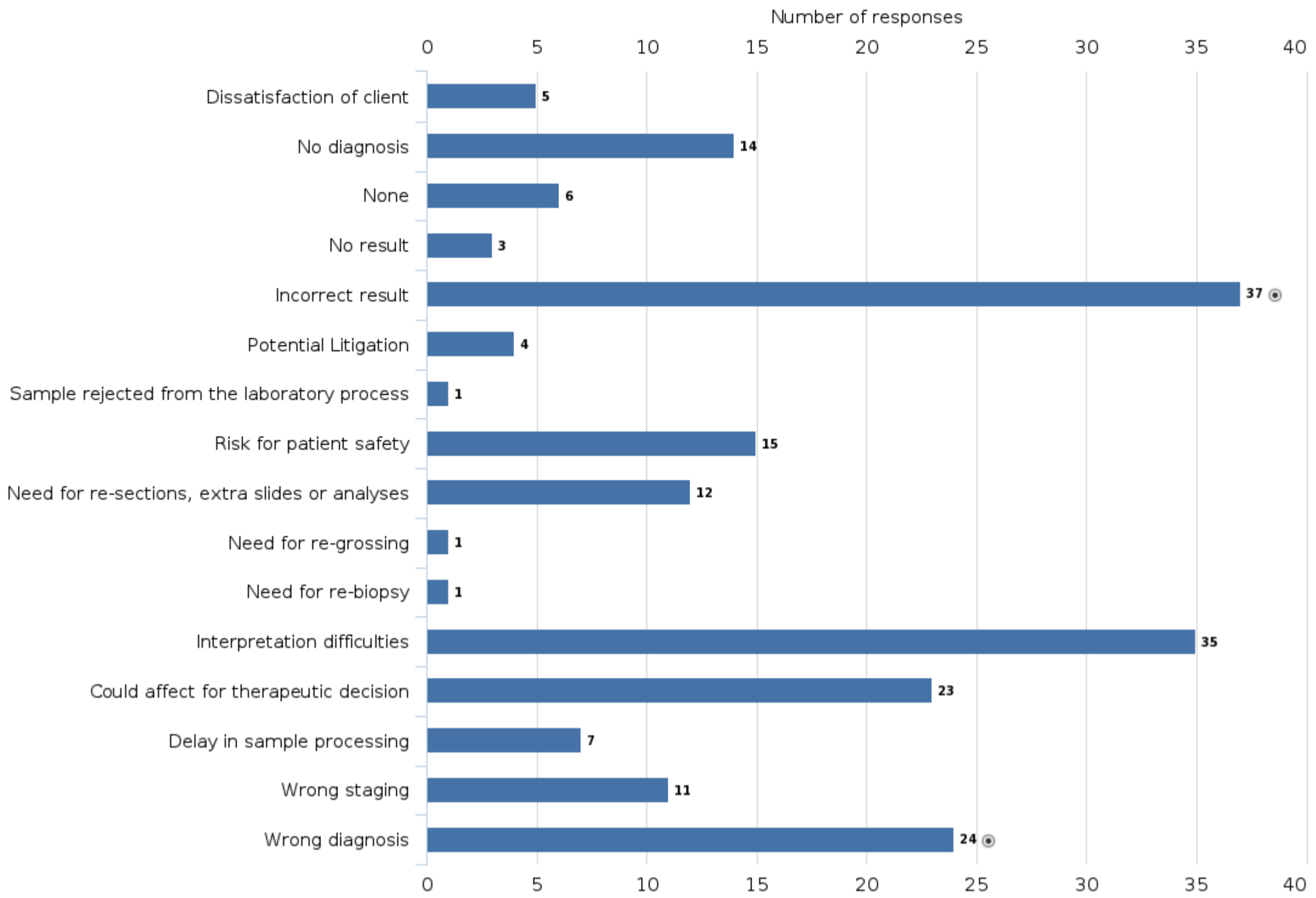
Ventana's Benchmark Ultra staining platform was used. Figure 1: Comparison of the different Melan A clones using melanoma and skin sections.

**What laboratory process error is present?**

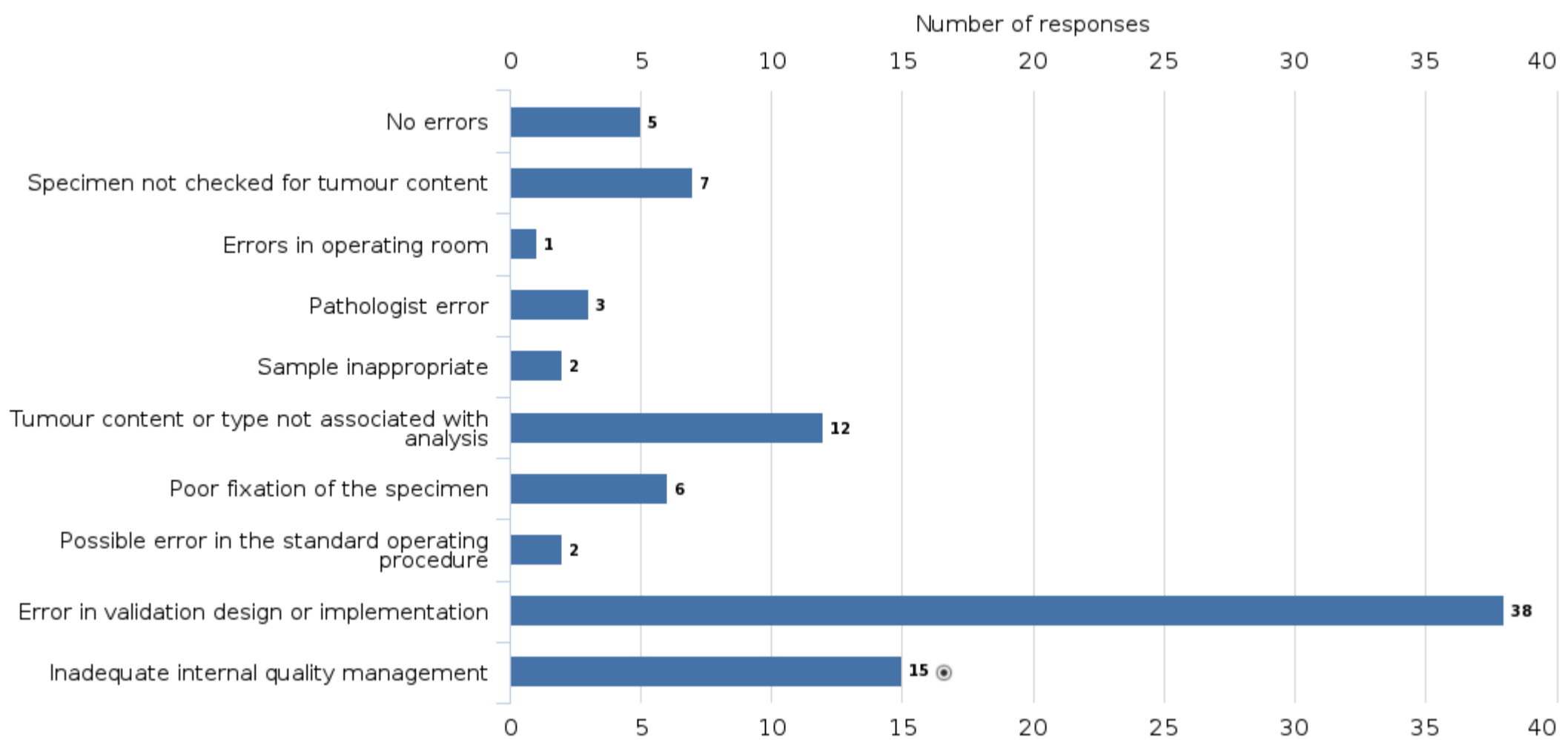




What are the implications on this case?



What can be the reasons behind this type of errors?



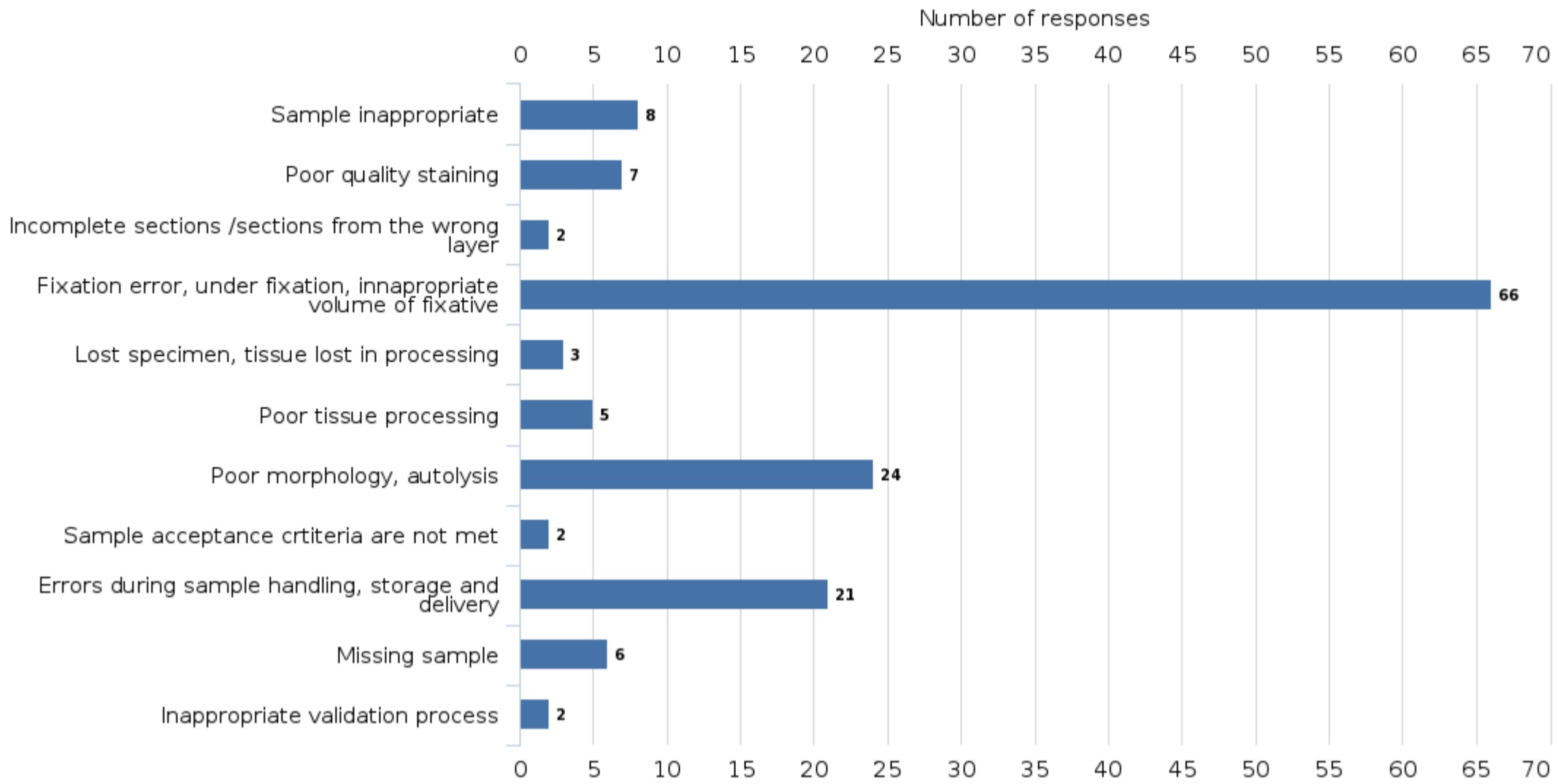
**Case 1**

The pathologists who interpreted gastroscopy specimens found that the tissue morphology of the biopsies from a certain department was partially impaired, and the interpretation of slides was also challenging by uneven staining. The interpretation was uncertain, and several samples required consultation and second opinions. Some pathologists asked to adjust stainings.

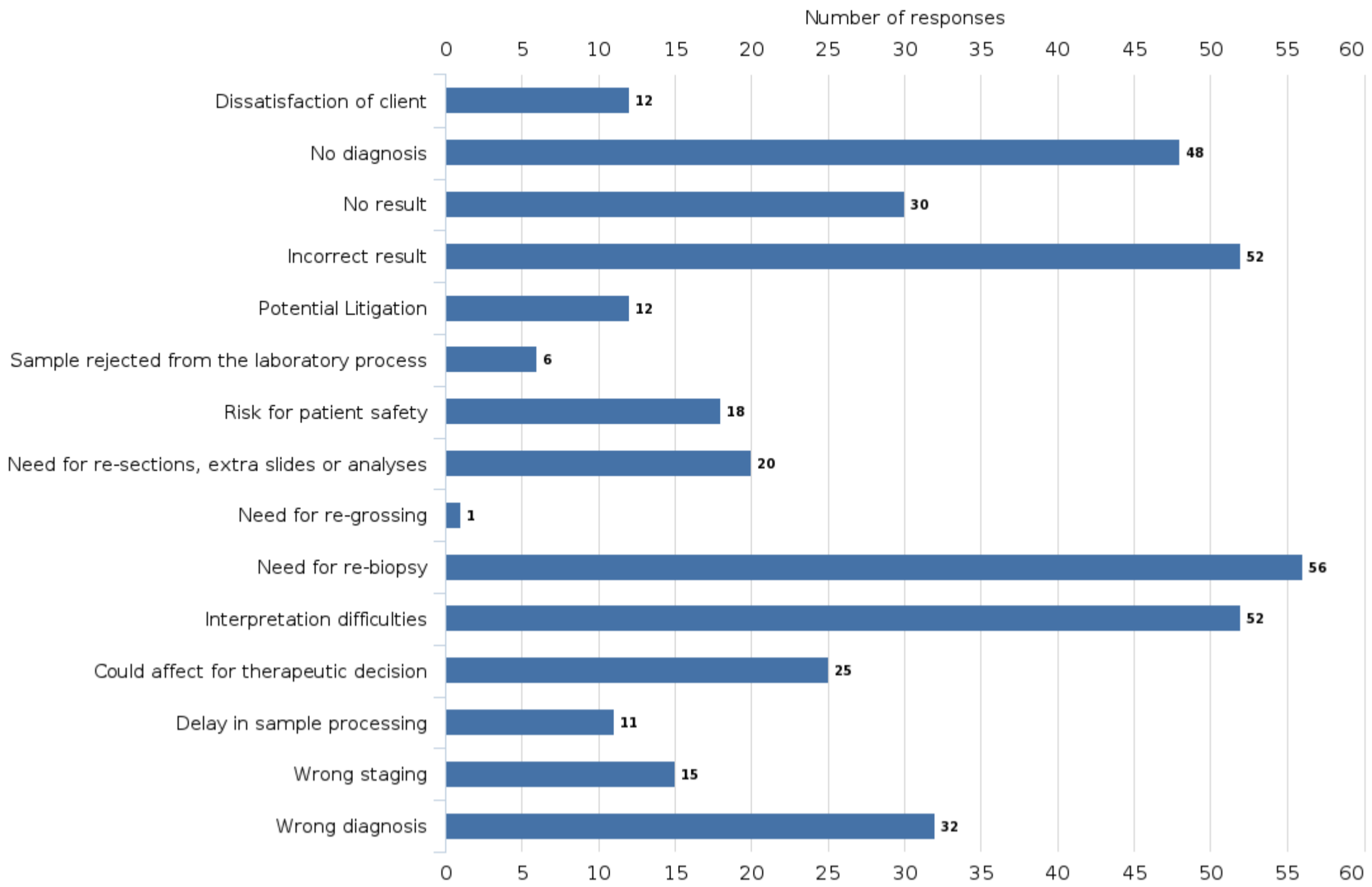
There was no mention of a deviation from laboratory processes in the laboratory information system. Only the quality manager of the laboratory commented on the increased number of lost biopsy samples. However, department had introduced new safety formalin containers that minimize exposure to formalin a few months ago.

What could be the reason for the weakened morphology and abnormal staining results? What could be the error in the laboratory process?

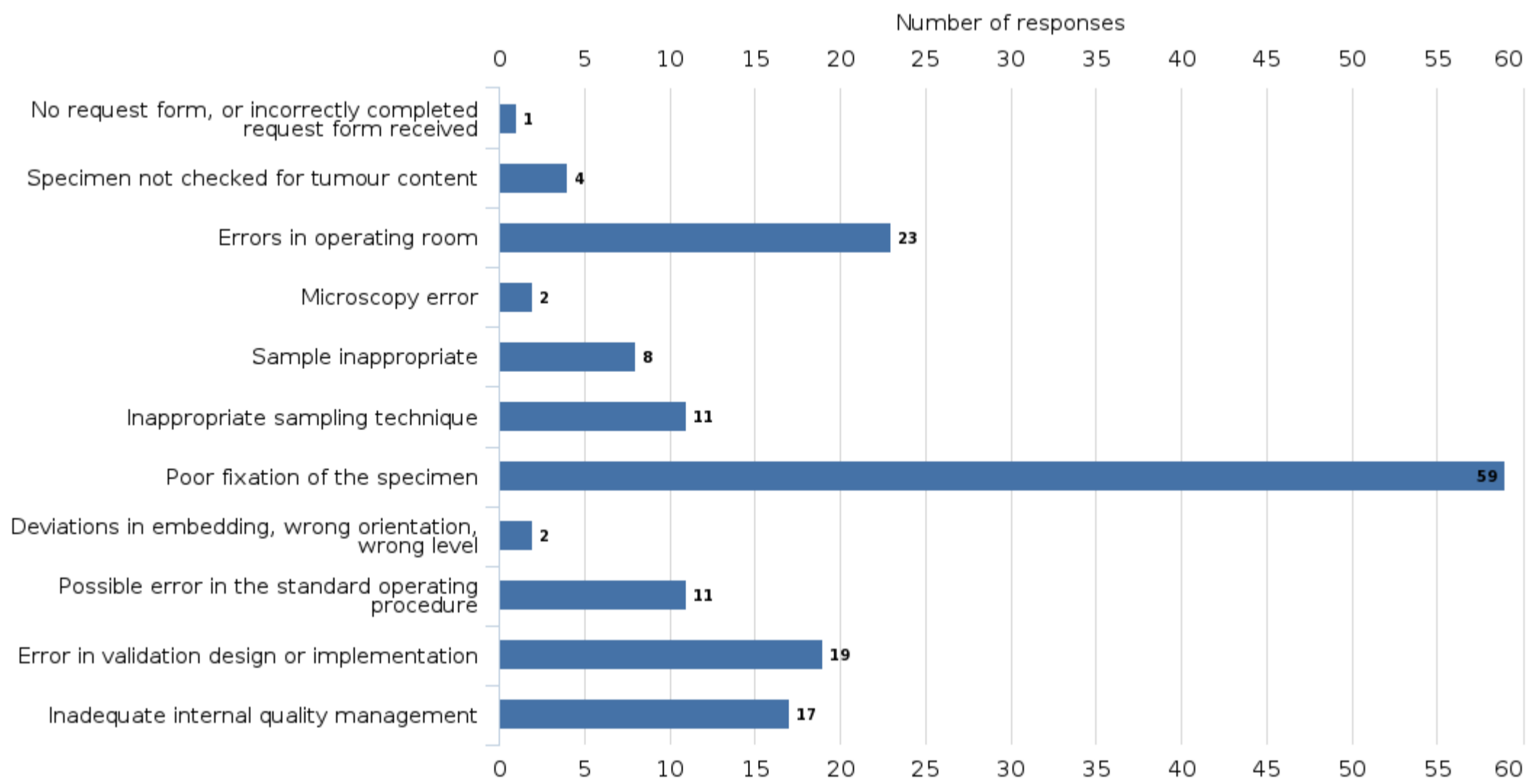
**What laboratory process error is present?**



**What are the implications on this case?**



**What can be the reasons behind this type of errors?**



**Case 2**

To make the process more efficient, the laboratory transferred a few special stains, such as GIEMSA and Congo red stains, from the fully automated special staining instrument to the high-capacity Sakura Prisma "Dipp and Dunk" type staining platform.

The protocols were designed to be as identical as possible in both instruments. The results of both staining platforms were compared in the validation processes. A quite similar staining result was obtained with both staining platforms. The stainings were optimized for digital pathology imaging and the results were interpreted utilizing the scanned whole slide images (WSI). Special attention was considering to the dehydration steps of the protocol. Remaining water deposits in slides on the last external quality assessment have been decreased results of current run.

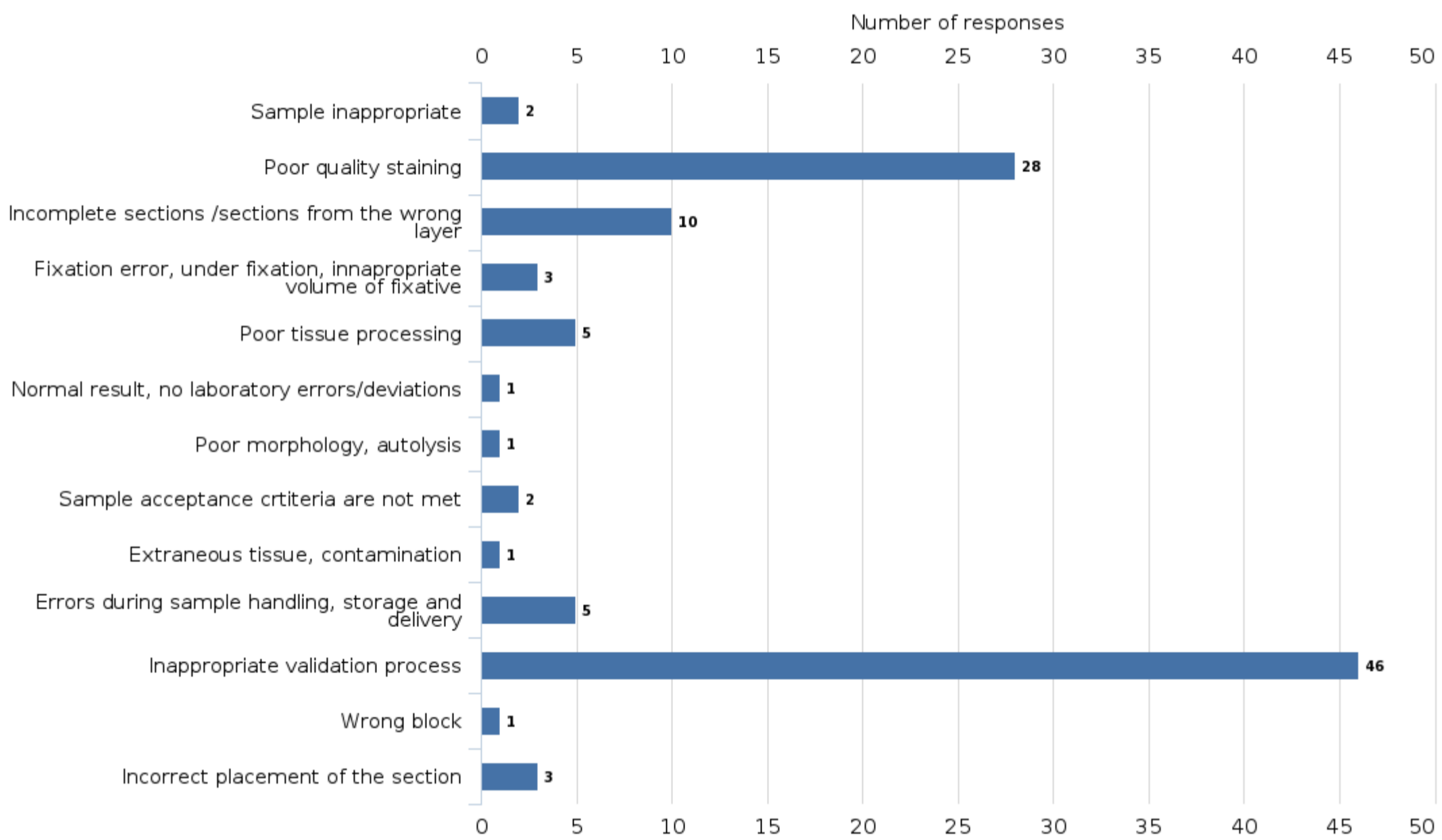
The quality and quantity of the control tissues was sufficient for the validation. For Congo red, high quality and wrinkle-free sections were microtomed using 4 µm thickness set up. Validation was performed with fresh staining solutions for one day. The device did not have diagnostic specimen glasses during validation process.

The essential validation documentation was done on time and the staff was informed about the changes. Post-validation monitoring of the device and staining quality was not actually done, because process audit of the routine and special histology stainings had been done about a month before the validation with no deviations.

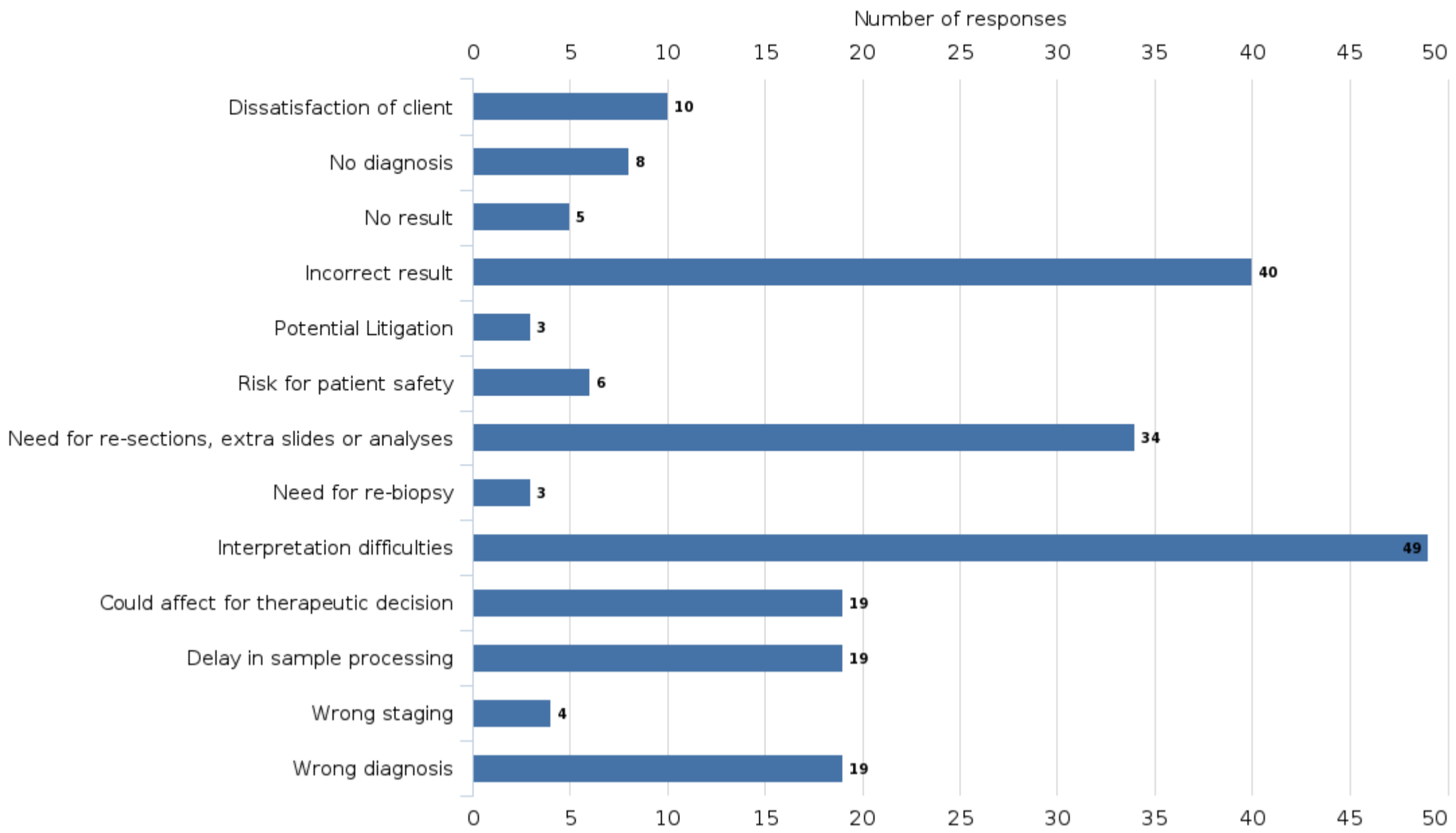
The staining process was the bottle neck of the laboratory process after validation and number of the restained slides increased significantly. However, some of the pathologists criticized the staining quality and some thought the staining quality were excellent.

Although a comparable staining result was obtained in the validation, has something possibly gone wrong and why has the number of repeated stainings increased?

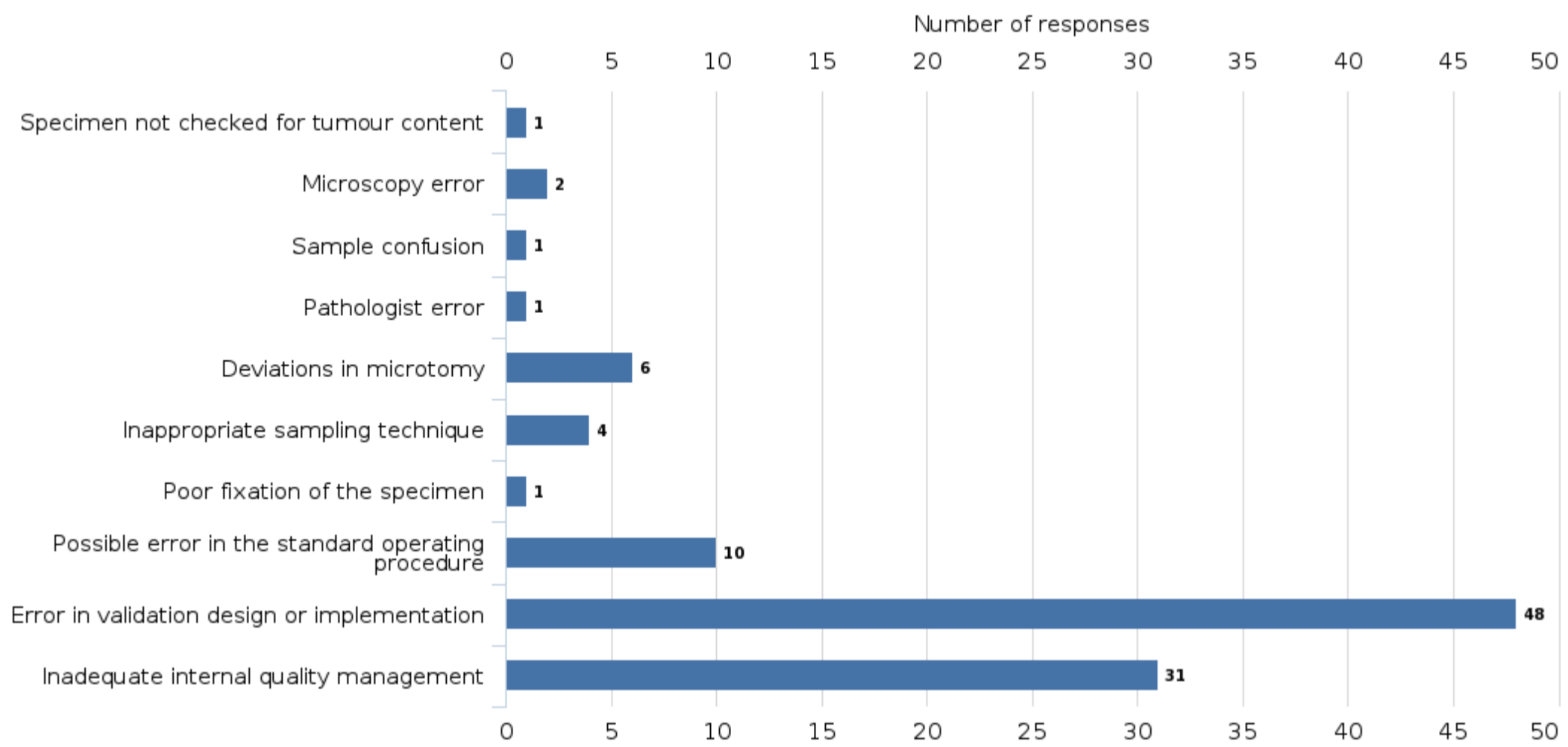
**What laboratory process error is present?**



What are the implications on this case?



What can be the reasons behind this type of errors?



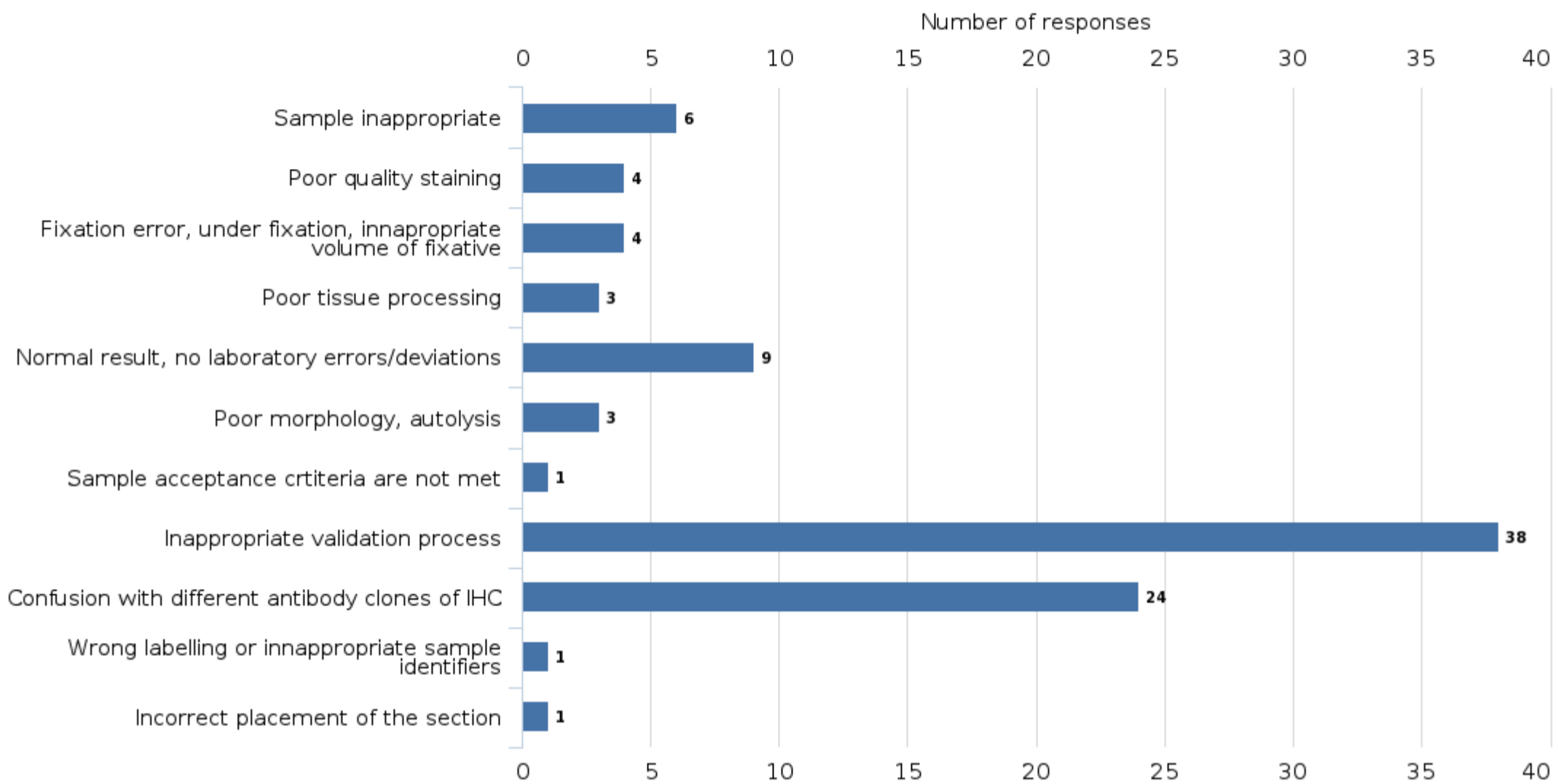
**Case 3**

After the conference related to skin and melanoma diagnostics, the laboratory decided to validate the new Melan A (MART1) antibody for immunohistochemistry and found that the new rabbit monoclonal Melan A (e.g. EP43) antibody and the mouse monoclonal BS52 antibody are clearly more sensitive than previously used mouse Melan A (A103) monoclonal antibody for melanoma cases.

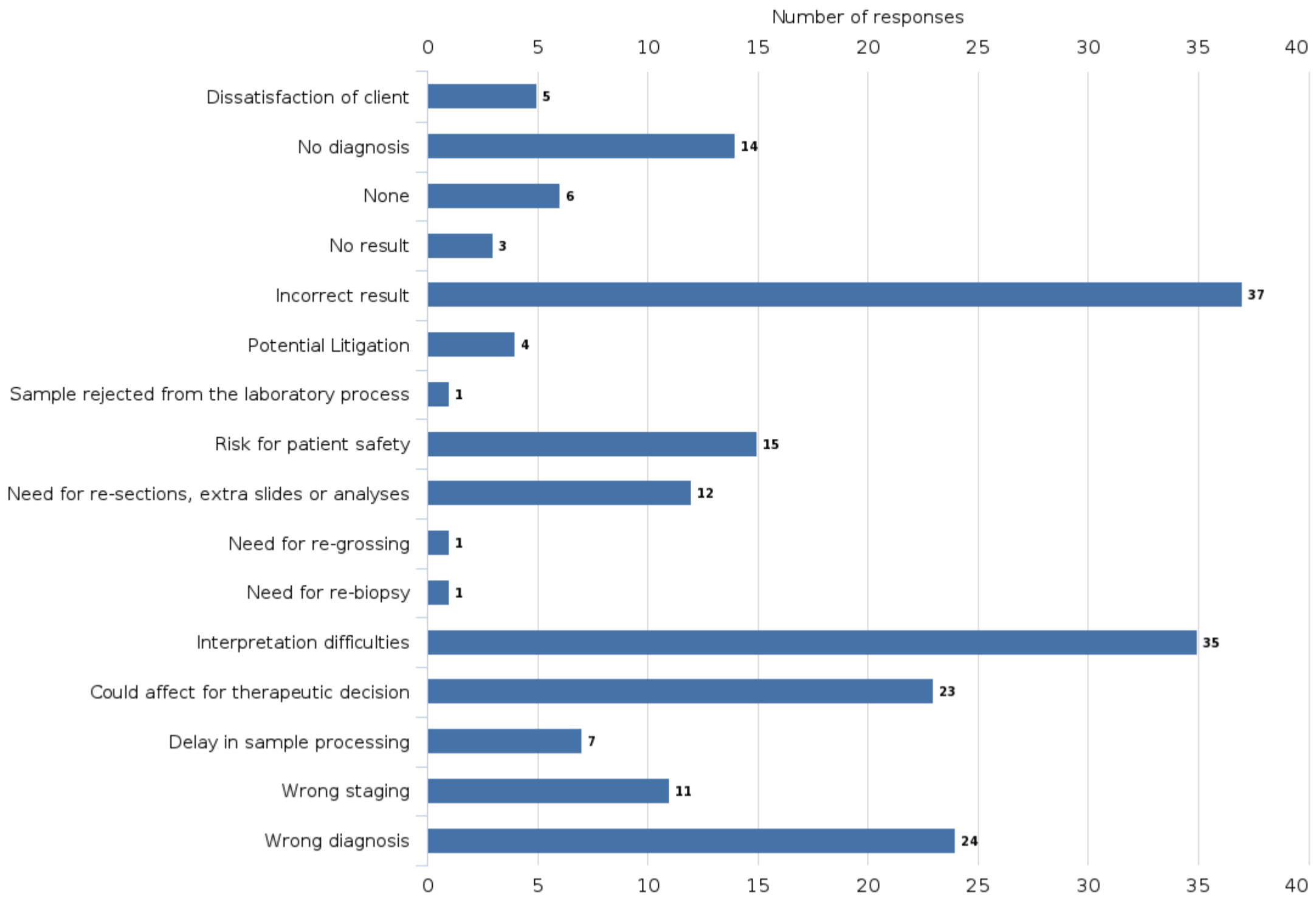
Several melanoma sections and normal benign skin sections were used as validation material. Skin and melanoma cases contained Melan A expression level from weak to very strong respectively. The validation was properly documented, and the A103 clone was changed to the BS52 clone due to its better sensitivity in melanoma diagnostic in Ventana Ultra platform. Later it turned out that the results were exceptionally weak in the diagnosis of adrenal and ovarian carcinoma, and even completely negative results were surprising.

Ventana's Benchmark Ultra staining platform was used. Figure 1: Comparison of the different Melan A clones using melanoma and skin sections.

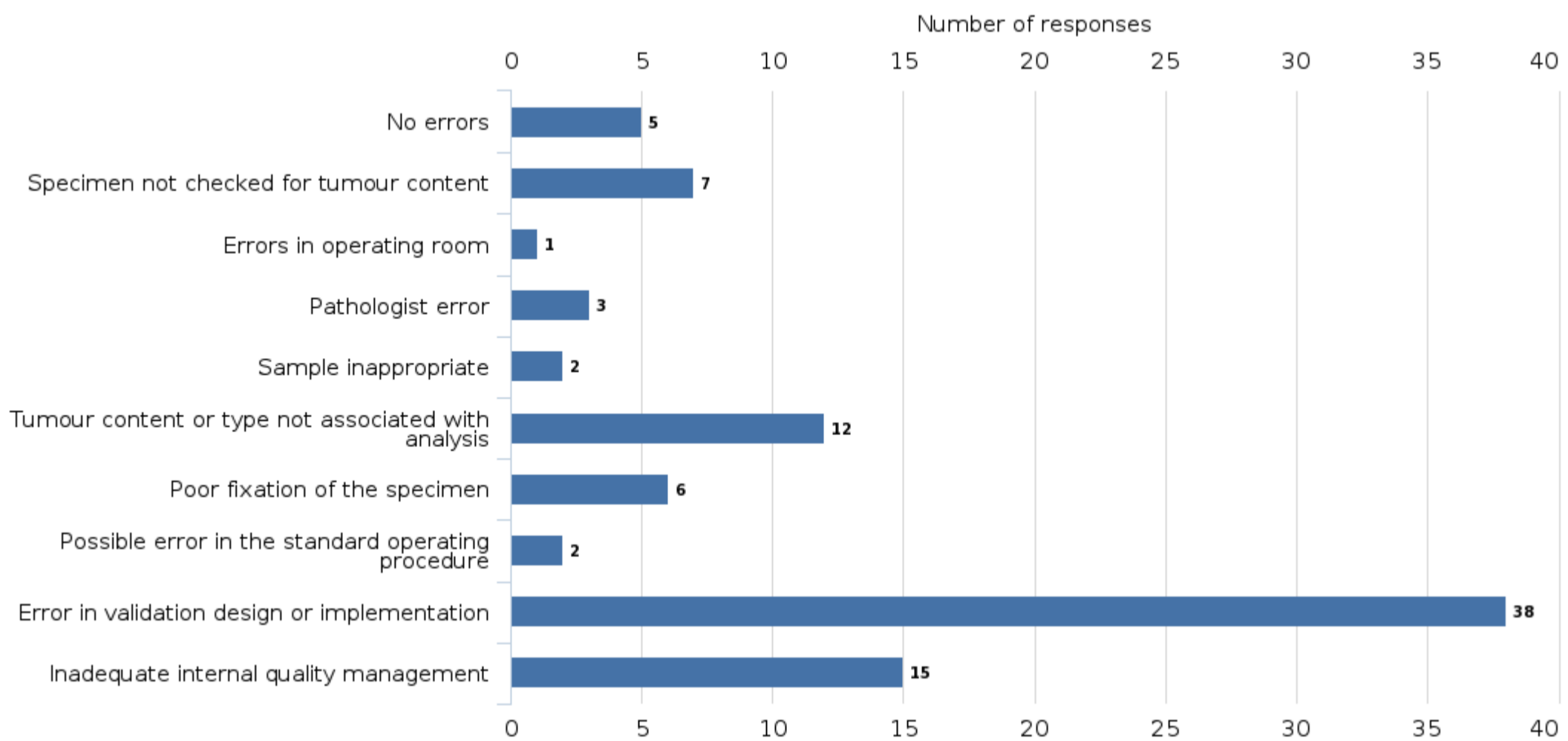
**What laboratory process error is present?**



What are the implications on this case?



What can be the reasons behind this type of errors?



External Quality Assessment Scheme

## Preanalytics and process in anatomic pathology Round 2, 2022

### Specimens

Samples S001–S003 (LQ779922021– LQ779922023) were case reports. In each case, participants were asked to identify potential preanalytical or laboratory process errors and to describe appropriate actions to be taken. It was possible to choose multiple errors per case from the list of errors given.

All the cases represented incidences that occur either in the laboratory or in other departments. Each case was an authentic example of situations that commonly occur in the laboratory and health care units.

### Report info

The final report contains the distribution of answers given. Your own laboratory's result is marked with a black radio button (☐). Common instruction guidelines on how to interpret the reports can be found under "LabScala user instructions" in LabScala.

The report includes a suggestion of what the correct course of action in each case should be. However, differences in valid courses of action may occur in different organizations or between different countries. The purpose of this assessment is to have participants deliberate and acknowledge the laboratories current procedures. The results are reported with an educational viewpoint. In case of questions regarding the reports, please contact the EQA coordinator.

### Comments – Expert

#### Case1

The pathologists who interpreted gastroscopy specimens found that the tissue morphology of the biopsies from a certain department was partially impaired, and the interpretation of slides was also challenging by uneven staining. The interpretation was uncertain, and several samples required consultation and second opinions. Some pathologists asked to adjust stainings.

There was no mention of a deviation from laboratory processes in the laboratory information system. Only the quality manager of the laboratory commented on the increased number of lost biopsy samples. However, department had introduced new safety formalin containers that minimize exposure to formalin a few months ago.

What could be the reason for the weakened morphology and abnormal staining results? What could be the error in the laboratory process?

#### What laboratory process error is present?

- Fixation error, under fixation, inappropriate volume of fixative
- Poor morphology, autolysis
- Errors during sample handling, storage and delivery

#### What are the implications on this case?

- No diagnosis
- No results
- Incorrect result
- Need for re-biopsy
- Interpretation difficulties

2023-01-03

### FINAL REPORT

Product no. 7806

Round opened	2022-11-29
Round closed	2022-12-22
Final report	2023-01-03

### Request for correction

Typing errors in laboratory's result forms are on laboratory's responsibility. Labquality accepts responsibility only for result processing. Requests must be notified by writing within three weeks from the date of this letter.

### Authorized by

EQA Coordinator  
Pia Eloranta  
pia.eloranta@labquality.fi

### Expert

Teppo Haapaniemi, M.Sc  
Medical Cell Biologist (Spec.)  
Fimlab Laboratories,  
Pathology, Tampere

### Labquality Oy

Kumpulantie 15  
FI-00520 HELSINKI  
Finland

Tel. + 358 9 8566 8200

Fax + 358 9 8566 8280

info@labquality.fi  
www.labquality.com





### What can be the reasons behind this type of errors?

- Errors in operating room
- Poor fixation of the specimen

Tissues with autolysis and abnormal morphology are often the result of failure of early preanalytical steps, such as fixation. Traditional formalin fixation and formalin containers have been the standard for a very long time. Recently there has been increased awareness about formalin exposure and the harm caused by formalin. To reduce the harm, safety containers have been developed that minimize exposure to formalin during sampling process.

Usually, two different types of deviations can occur with the type of safety container shown in the picture. Deviations affect the quality of the tissue sample. The sample can remain in the buffer part of the two-part safety container and formalin is not released into the buffer containing part of the container. In this case, the sample cannot be fixed properly, and autolysis weakens the quality of the sample. Formalin is released through the holes of the cap and common deviation is that the holes should be closed after releasing of the formalin. During transport, small samples can move through the holes to another part of the jar. The sample may remain dry or not all samples can be found in the jar. It should be noted that the formalin part of the container cannot be opened.

With the introduction of safety containers, the interaction between the pathology laboratory and the sending departments is further emphasized. Sufficient user orientation must be ensured, and users' competence must be ensured. It is also essential to consider internal quality assurance and monitoring. A significant increase in the number of deviations, such as "insufficient for diagnosis", may indicate the incorrect usage of the safety containers during sampling.



Figure 1. Safety container of formalin. The fixative has been properly released into the container from the upper fixative part of the container. After releasing the formalin, the cap should be closed tightly.

### Case 2

To make the process more efficient, the laboratory transferred a few special stains, such as GIEMSA and Congo red stains, from the fully automated special staining instrument to the high-capacity Sakura Prisma "Dipp and Dunk" type staining platform.

The protocols were designed to be as identical as possible in both instruments. The results of both staining platforms were compared in the validation processes. A quite similar staining result was obtained with both staining platforms. The stainings were optimized for digital pathology imaging and the results were interpreted utilizing the scanned whole slide images (WSI). Special attention was considering to the dehydration steps of the protocol. Remaining water deposits in slides on the last external quality assessment have been decreased results of current run.

The quality and quantity of the control tissues was sufficient for the validation. For Congo red, high quality and wrinkle-free sections were microtomed using 4 µm thickness set up. Validation was performed with fresh staining solutions for one day. The device did not have diagnostic specimen glasses during validation process. The essential validation documentation was done on time and the staff was informed about the changes. Post-validation monitoring of the device and staining quality was not actually done, because process audit of the routine and special histology stainings had been done about a month before the validation with no deviations.

The staining process was the bottle neck of the laboratory process after validation and number of the restained slides increased significantly. However, some of the pathologists criticized the staining quality and some thought the staining quality were excellent.

Although a comparable staining result was obtained in the validation, has something possibly gone wrong and why has the number of repeated stainings increased?

**What laboratory process error is present?**

- Incomplete sections /sections from the wrong layer
- Poor quality staining
- Inappropriate validation process

**What are the implications on this case?**

- Incorrect result
- Need for re-sections, extra slides or analyses
- Interpretation difficulties

**What can be the reasons behind this type of errors?**

- Deviations in microtomy
- Error in validation design or implementation
- Inadequate internal quality management

This case contained several different types of problems related to the staining, validation, or analyzing the results.

**The case involved the following laboratory process problems:**

- Error in planning, implementation and monitoring of validation.
- It is difficult to verify the identity of the protocols of the fully automatic platform and the “dip and dunk” type device.
- Dehydration phases may be too long in protocol. The lengths of the dehydration steps of the new instrument are not necessarily set to be exact.
- Thickness of the sections for Congo staining is not optimal.
- Polarization has not been taken into account in the interpretation of the Congo staining, but the microscopy has been made with bright field of the of the whole slide images.

**Error in planning, implementation and monitoring of validation**

In this case, eg. Giemsa and Congo red staining methods were transferred from a special staining instrument to a Dipp and Dunk type staining platform. Therefore, the staining solution exchange interval should be taken into account better during the validation. The staining steps performed in the validation, should be extend to at least the length of the planned solution exchange interval. Staining should be done with fresh solutions, as well as with solutions that have stained the number of glasses. It should be noted that the staining solutions may develop further during storage and staining, and the intensity can increase or as is typical, the intensity of the staining will decrease. This causes variation in the staining results, and in validation it is important to determine the variety of the staining intensity between the changing intervals of the solutions. The variety of the intensity should be kept as low as possible.

The follow-up of the validation should have been considered better, which in this example case was not actually done at all, referring to the process audit, which have been done a month before the validation. However, auditing has nothing to do with the validation method. It would have been essential to move the audit to the future, which would have covered the process of the changed staining methods. Deficiencies in validation have directly affected the staining results and there are no guarantees about the quality of the staining. Revalidation should be done without delay.

**It is difficult to verify the identity of the protocols of a fully automatic device and a dip and dunk type device. Dehydration steps may be too long. The lengths of the dehydration stages of the new device are not necessarily set to be exact.**

It should be noted that the fully automatic special staining instrument is tailored to stain individual slides with separately, so all times are exact for these slides. The times of the Dip and Dunk type device are not necessarily set to be exact in the protocol, but if the device is busy for significant number of slides, the slides can be in solutions for a significantly longer time than the time set in the protocol. This is one possible factor for intensity variations after staining validation. Dehydration times of Congo and Giemsa staining must be kept sufficiently short and exact, because prolonged dehydration times is a risk for the stains which could washed into the alcohol series during dehydration.

**The section thickness for Congo Red staining is not optimal. Polarization has not been taken into account in the microscopy of the Congo Red staining, but the interpretation has been made with bright field of the of the whole slide images.**

The 4 µm section thickness used in the validation. The recommended section thickness for Congo Red staining is a slightly thicker section than normal section thickness (4 µm). Too thin section leads to too weak staining of amyloid fibers. The section thickness is typically around 6 µm to 10 µm. This enables the separation of amyloid fibers by polarization, whereby the fibers are separated in the correct shade (apple green) in microscope. If the section is too thin, the interpretation becomes difficult during polarization. The right wavelengths of light (blue and yellow) do not get through properly. Too thin section appears as a bluish shade because the yellow wavelength is blocked. If the section is too thick, amyloid appears yellow to orange, because the red and blue wavelengths are blocked. In this case, the stainings have been interpreted using bright field from whole slide images utilizing digital pathology. However, the result of Congo red staining should always be verified using polarized light, which was not done in this validation process.

### Case 3

After the conference related to skin and melanoma diagnostics, the laboratory decided to validate the new Melan A (MART1) antibody for immunohistochemistry and found that the new rabbit monoclonal Melan A (e.g. EP43) antibody and the mouse monoclonal BS52 antibody are clearly more sensitive than previously used mouse Melan A (A103) monoclonal antibody for melanoma cases.

Several melanoma sections and normal benign skin sections were used as validation material. Skin and melanoma cases contained Melan A expression level from weak to very strong respectively. The validation was properly documented, and the A103 clone was changed to the BS52 clone due to its better sensitivity in melanoma diagnostic in Ventana Ultra platform.

Later it turned out that the results were exceptionally weak in the diagnosis of adrenal and ovarian carcinoma, and even completely negative results were surprising.

Ventana's Benchmark Ultra staining platform was used.

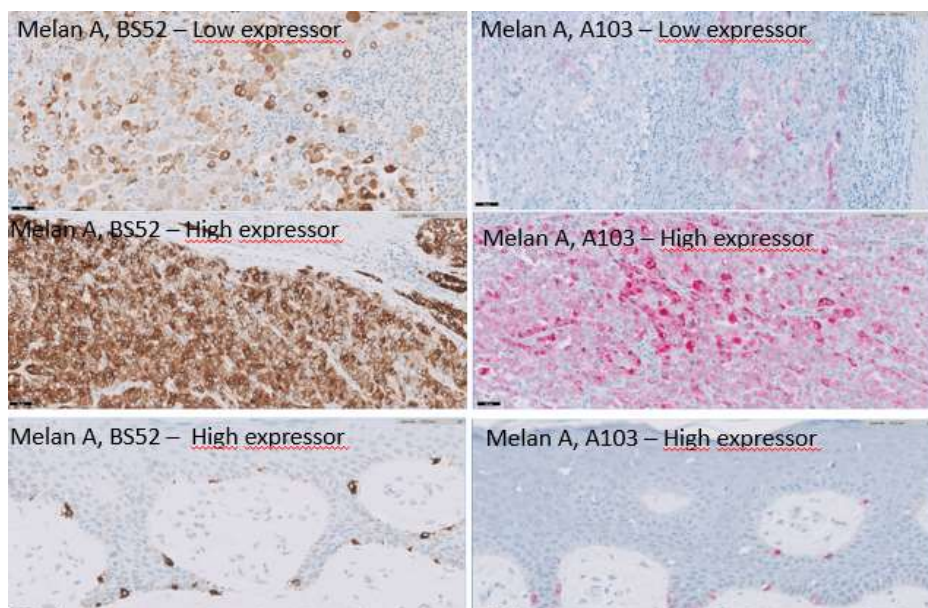


Figure 2: Comparison of the different Melan A clones using melanoma and skin sections.

#### What laboratory process error is present?

- Inappropriate validation process
- Confusion with different antibody clones of IHC

#### What are the implications on this case?

- Incorrect result
- Need for re-sections, extra slides or analyses
- Interpretation difficulties

#### What can be the reasons behind this type of errors?

- Error in validation design or implementation

#### Errors in validation planning, communication and clone selection

In this case, the antibody validation was done in such a way that the new Melan A antibody replaced the previous antibody. The results showed that the sensitivity of the new clone is better than the A103 clone in melanoma diagnostics (Figure 3 a and b). However, the validation did not take into account the specific cross-reaction of the

A103 clone to steroid-producing tissues, such as the adrenal gland or other steroid-producing cell types and tumours. Therefore, the BS52 clone remained negative in steroid-positive samples that were positive for the A103 clone (Figure 3 c). The problem in the case was errors in validation and confusion in clone selections. The test material did not contain steroid-positive tissues, which should have been taken into account in accordance with the intended use of the staining. Validation should always take into account the uses of staining in diagnostic purpose, if this is possible. It is also worth noting that in validation with clone comparison, staining should be compared using the same detection method, if it is possible.

It is not always necessary to replace the antibody, but the new antibody can be used alongside another clone and the target of use can be directed to suit each antibody. After the approval of the validation, it should also be remembered to provide adequate information about the changes. Ideally, the BS52 clone would be used in melanoma diagnostics and the A103 clone in the diagnostics of steroid-producing samples. It should be noted that there is a variation in the staining results on different staining platforms regarding the optimal staining of the clones. This should also be taken into account in the validation process of the antibodies.

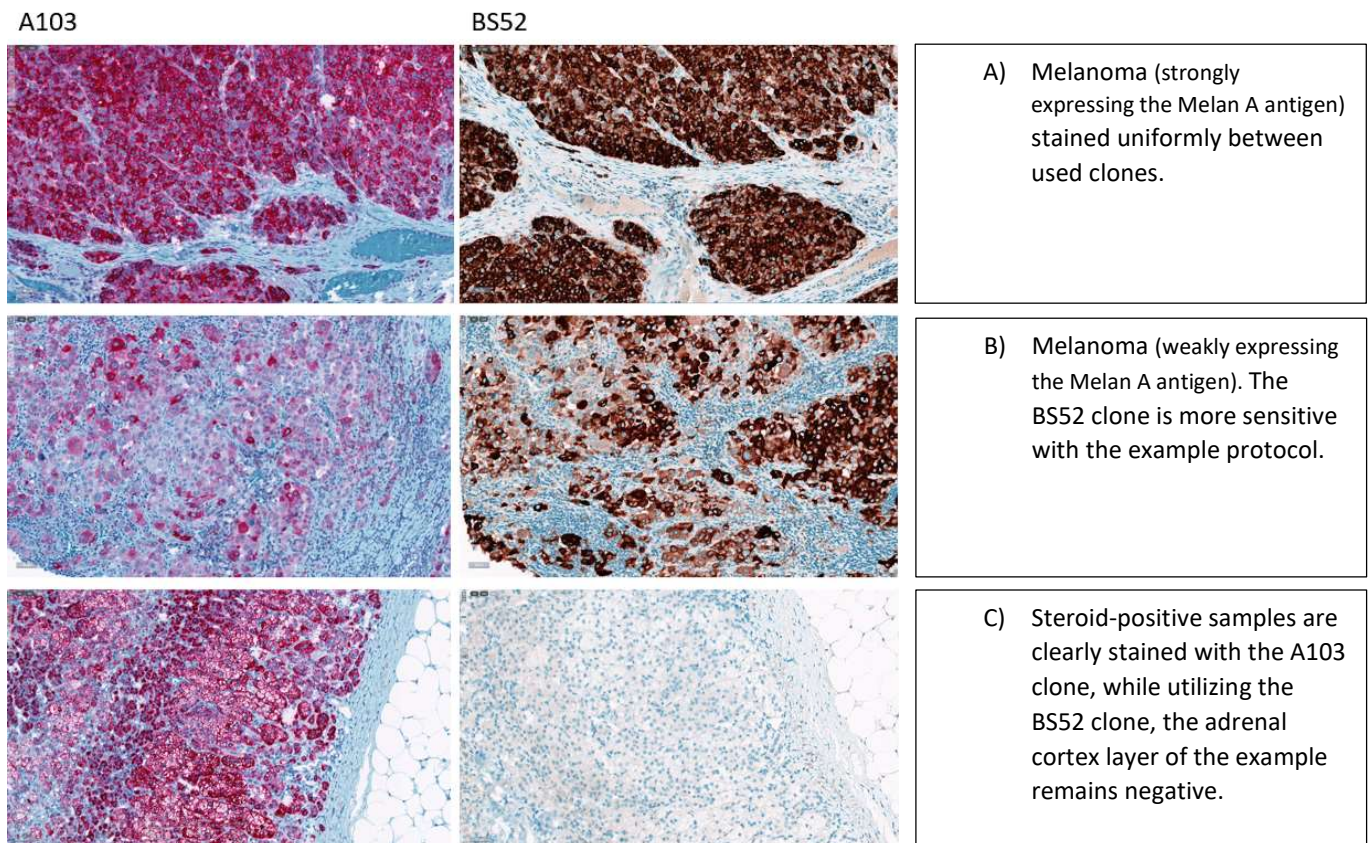


Figure 3. Melanoma cases and the adrenal cortex stained with two different detection methods and antibody clones. Noteworthy is the difference in sensitivity of the clones in melanoma cases and the cross-reaction of the A103 clone to the steroid-producing cells of the adrenal cortex cell layer.

### Overall comment

The purpose of this assessment was to examine deviations from the point of view of sample handling, storage and delivery, as well as from the point of view of validation and implementation of the methods. The use of safety containers will increase in the future, so laboratories should be prepared for the related problems. Sufficient instructions in use have a great impact on the quality of the samples. Cooperation with the sending units ensures the correct use of safety containers and thus a better quality of the samples.

The laboratories well knew the essential deviations and errors from these exemplary cases. The correlation between the laboratories was good, although there was a small dispersion between the results. It is worth noting, that the laboratory's additional comments had an excellent description of the problem and related solutions.

### End of report

Copyright © Labquality Oy

Labquality does not permit any reproduction for commercial purposes of any portion of the material subject to this copyright. Labquality prohibits any use of its name, or reference to Labquality EQA program, or material in this report in any advertising, brochures or other commercial publications. Labquality EQA data do not necessarily indicate the superiority of instruments, reagents, testing equipments or materials used by participating laboratories. Use of Labquality EQA data to suggest superiority or inferiority of equipments or materials may be deceptive and misleading. Proficiency test results are handled confidentially. Labquality will not issue any statements to third parties of the performance of laboratories in external quality assessment schemes unless otherwise agreed.