

External Quality Assessment Scheme

Clinical cytology: Gynaecological cytology (liquid), virtual microscopy Round 1, 2022

Specimens

Please find enclosed 6 specimens as cases with virtual microscopy images.

Background information

Specimens are gynaecological, Papanicolaou stained cytology pap smear samples. The whole specimen slide has been scanned. Papanicolaou stained cytological slides were chosen from routine material of a pathology laboratory. Age of the patient and information about point of menstrual cycle, hormone therapy, contraception and clinical history are given when available.

Parameters

Please see page 2.

Result reporting

Please enter the results and methods via LabScala (www.labscala.com). Please use Mozilla Firefox or Google Chrome as a web browser when using LabScala. Do not use Internet Explorer. If you have problems viewing the slides and you see the Aiforia logo only but no slides, please ask your IT department to allow access to webpage <http://cloud.aiforia.com>.

Results can be entered and changed as long as the round is still open, so even if those are already sent to Labquality. Change your results, save as final and remember to send results again.

CASES

S001, Case 1 (LQ779522011)

Female 54 yr. 2017 a solid tumorlike process ca 6.5 cm, was detected in the uterine corpus. No symptoms. Annual cytology controls recommended. Now a control LBC sample.

S002, Case 2 (LQ779522012)

Female 62 years. Previously treated for squamous cell carcinoma of the skin. Recently an abnormal ultrasound sonography of the uterine corpus. No uterine discharge. An LBC sample was taken.

S003, Case 3 (LQ779522013)

Female, 66 years. Several years ago hysterectomy due to uterine prolapse. Previously HPV-positive. Now a control LBC sample from the vagina.

S004, Case 4 (LQ779522014)

Female, 43 years. 2 years ago LEEP-cone due to LSIL. Postoperatively HPV positive. Now colposcopy was performed and no acetowhite staining of epithelium was observed. LBC sample was taken.

S005, Case 5 (LQ779522015)

Female 59 years old. Uterine discharge was observed. LBC sample from the uterine cervix.

S006, Case 6 (LQ779522016)

Female, 79 years. Postmenopausal bleeding. Uterine ultrasound was abnormal. LBC sample was taken.

2022-07-05

INSTRUCTIONS

Product no. 6701
LQ779522011-016/FI

Subcontracting: Digital image services

The results should be reported no later than
August 18, 2022.

Inquiries

EQA Coordinator
Pia Eloranta
pia.eloranta@labquality.fi

Labquality Oy

Kumpulantie 15
FI-00520 HELSINKI
Finland

Tel. + 358 9 8566 8200
Fax + 358 9 8566 8280

info@labquality.fi
www.labquality.com



Parameters

This round assesses diagnostics of cervico-vaginal and endometrial cellular atypias. Epithelial abnormalities of the gynaecological Papanicolaou stained smears should be classified according to the modified Bethesda system (TBS 2001). It is voluntary to give the Papanicolaou classification (Classes 0–5). The circles in samples are only routine markings. Important findings may also be found outside of these markings.

Responses from individual pathologists are requested instead of responses based on group consensus. Interpretations should be made as similarly as possible compared to patient cases. It is possible to return multiple results/case (1-5 respondents). Although in every day work you must often give several different diagnoses or interpretations, only one diagnosis of each case per respondent is wished. This will make final analysis easier.

It is important to take into account that this external quality assessment scheme does not evaluate cytological examination as a medical consultation. Only the most important parameters, especially cellular atypia, have been chosen to obtain a comprehensible final report.

Papanicolaou class (voluntary):

Please give the Papanicolaou classification only if you use it in your normal routine.

0 (not representative), 1 (normal), 2 (benign atypia), 3 (suspect), 4 (clearly suspect) or 5 (malignant).

Specific diagnosis:

trichomonas

fungal organism

actinomyces/ALO

herpes

negative for intraepithelial lesion and malignancy, NILM

inflammation/regeneration

atrophic vaginitis

radiation change

IUD change

atypical squamous cells of undetermined significance, ASC-US

atypical squamous cells, cannot exclude HSIL, ASC-H

low grade SIL (CIN1, slight dysplasia, HPV)

high grade SIL (CIN2, moderate dysplasia, CIN3, severe dysplasia, CIS)

squamous cell carcinoma, also suspicion

benign endometrium

atypical glandular cells of undetermined significance, AGC-NOS

atypical glandular endocervical cells of undetermined significance, AGC-NOS

atypical glandular endometrial cells of undetermined significance, AGC-NOS

atypical glandular cells, favour neoplastic, AGC-FN

atypical glandular endocervical cells, favour neoplastic, AGC-FN

atypical glandular endometrial cells, favour neoplastic, AGC-FN

adenocarcinoma in situ, AIS

cervical adenocarcinoma

endometrial adenocarcinoma

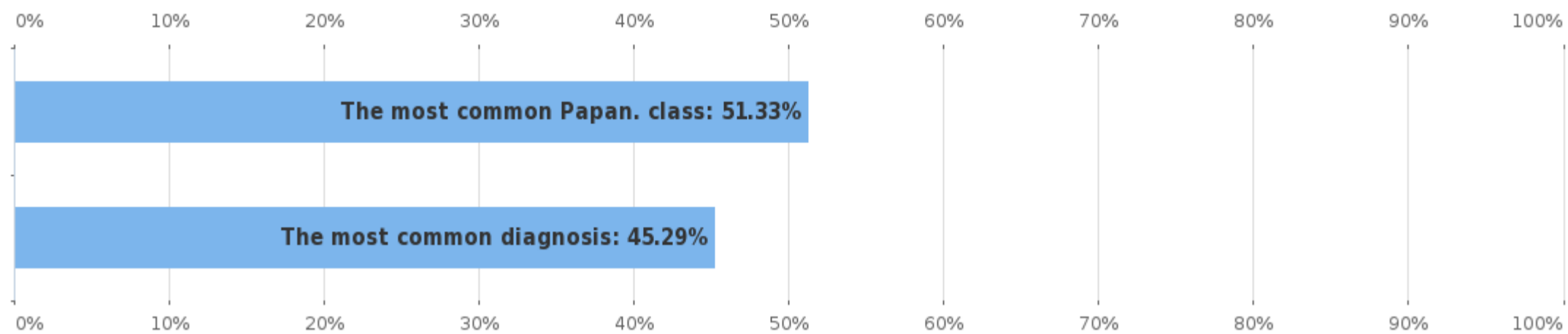
extrauterine adenocarcinoma

other malignant neoplasm

other finding

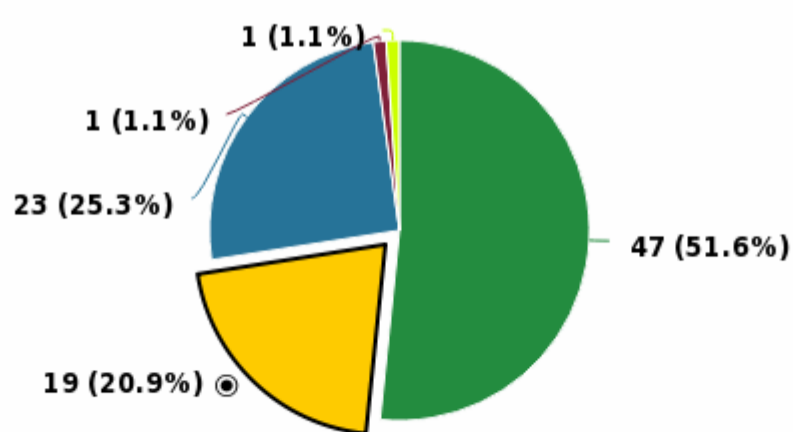
Round	No of participants	No of responded participants	Response percentage %
Gynaecological cytology (liquid based), virtual microscopy, May, 1-2022	121	111	91.74%

Agreement percentage of the responses

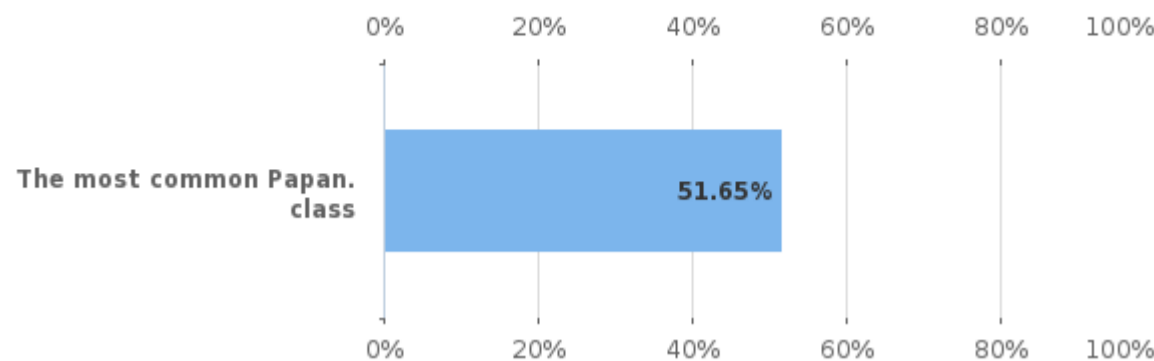


Sample S001 | Papanicolaou class

Papanicolaou class



Papanicolaou class %

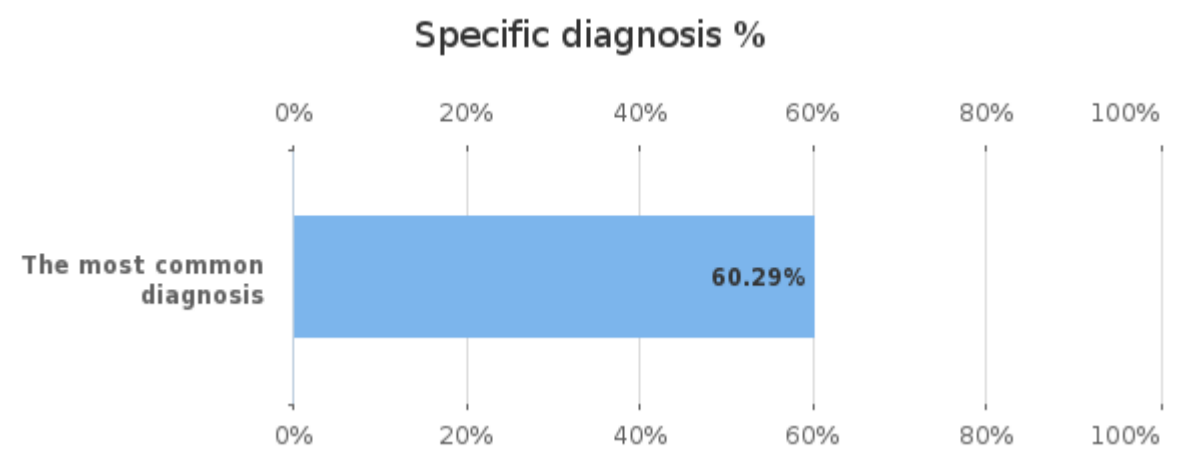
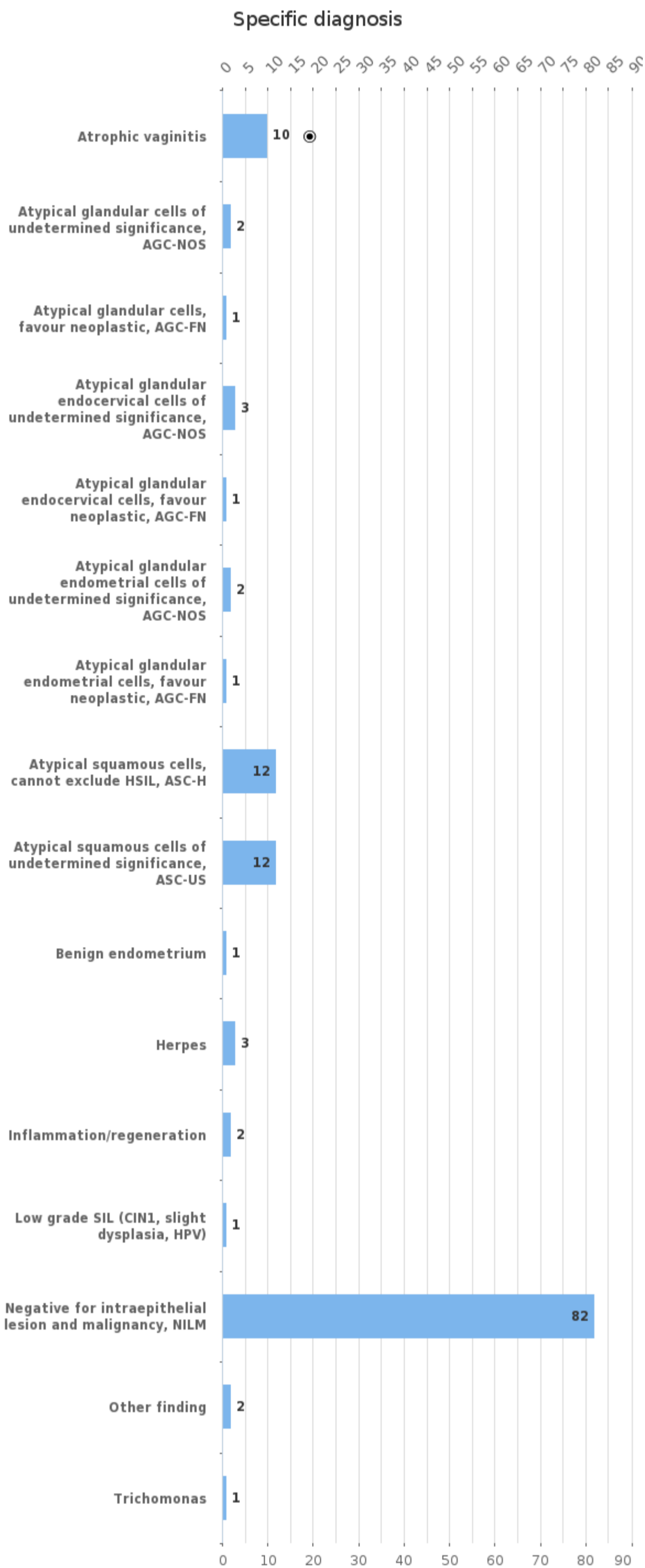


■ 1 (normal)
 ■ 2 (benign atypia)
 ■ 3 (suspect)
 ■ 4 (clearly suspect)
 ■ 5 (malignant)

Papanicolaou class	n
1 (normal)	47
2 (benign atypia)	19
3 (suspect)	23
4 (clearly suspect)	1
5 (malignant)	1
Total	91

Agreement percentage of the responses	%
The most common Papan. class	51.65

Sample S001 | Specific diagnosis

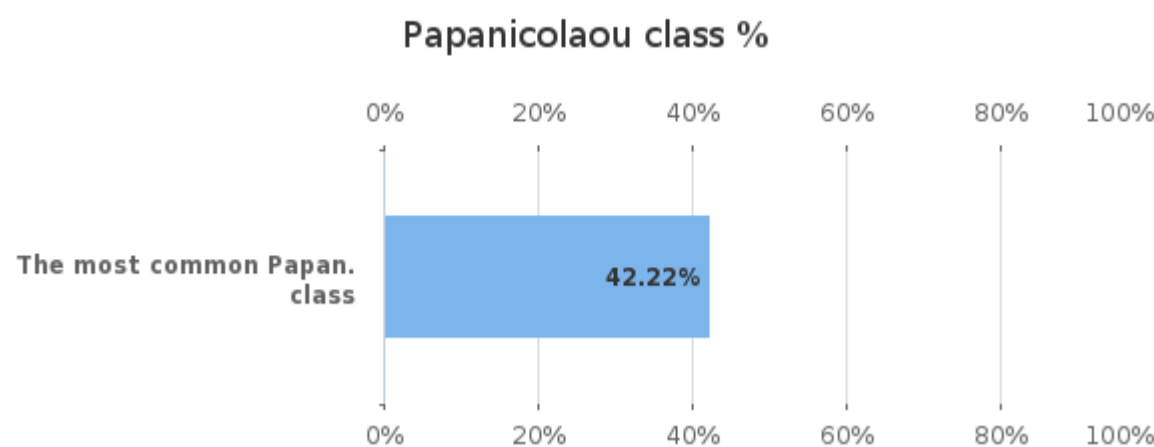
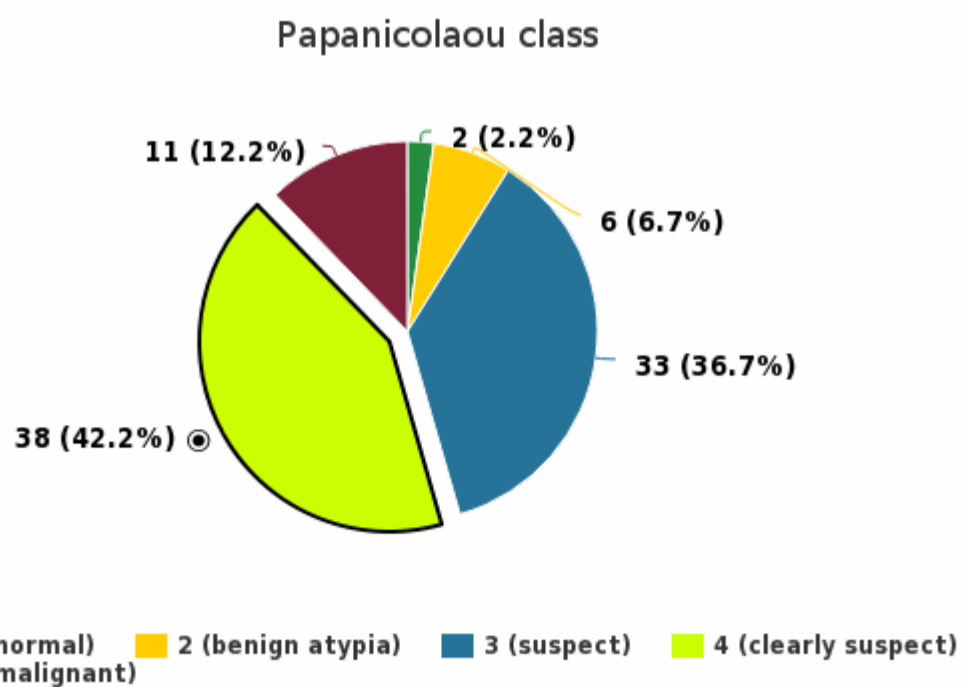


Specific diagnosis	n
Atrophic vaginitis	10
Atypical glandular cells of undetermined significance, AGC-NOS	2
Atypical glandular cells, favour neoplastic, AGC-FN	1

Agreement percentage of the responses	%
The most common diagnosis	60.29

Atypical glandular endocervical cells of undetermined significance, AGC-NOS	3
Atypical glandular endocervical cells, favour neoplastic, AGC-FN	1
Atypical glandular endometrial cells of undetermined significance, AGC-NOS	2
Atypical glandular endometrial cells, favour neoplastic, AGC-FN	1
Atypical squamous cells, cannot exclude HSIL, ASC-H	12
Atypical squamous cells of undetermined significance, ASC-US	12
Benign endometrium	1
Herpes	3
Inflammation/regeneration	2
Low grade SIL (CIN1, slight dysplasia, HPV)	1
Negative for intraepithelial lesion and malignancy, NILM	82
Other finding	2
Trichomonas	1
Total	136

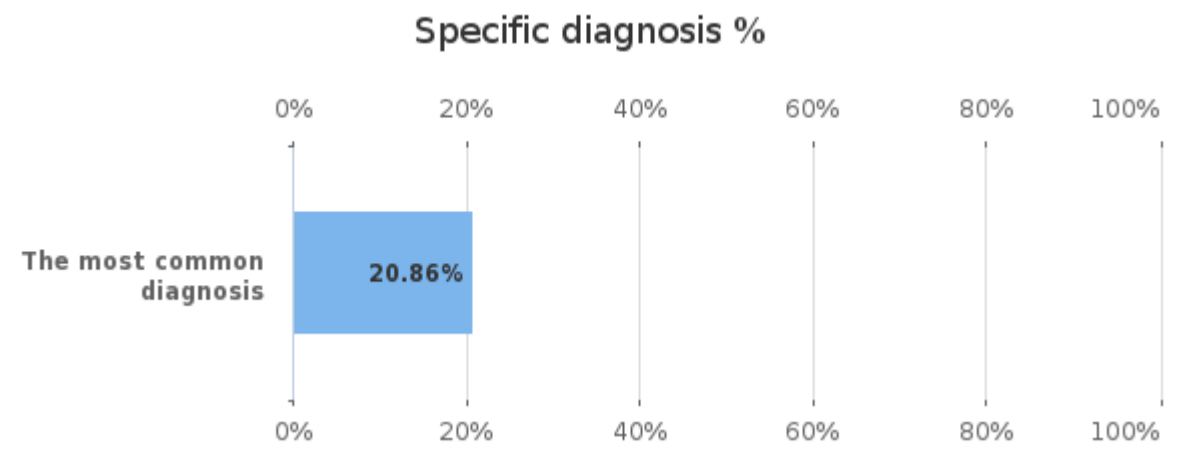
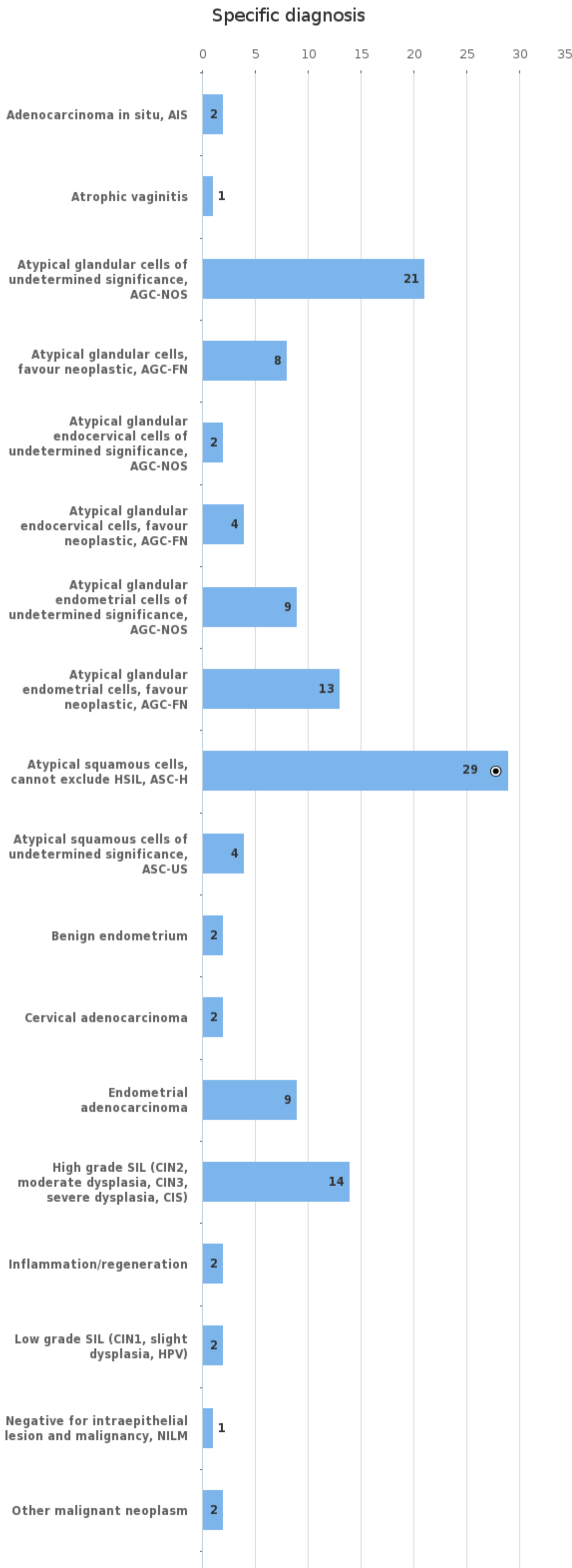
Sample S002 | Papanicolaou class

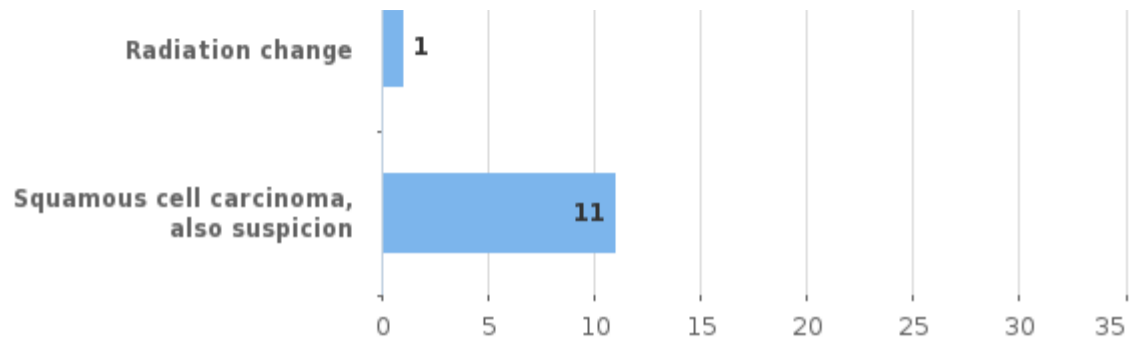


Papanicolaou class	n
1 (normal)	2
2 (benign atypia)	6
3 (suspect)	33
4 (clearly suspect)	38
5 (malignant)	11
Total	90

Agreement percentage of the responses	%
The most common Papan. class	42.22

Sample S002 | Specific diagnosis

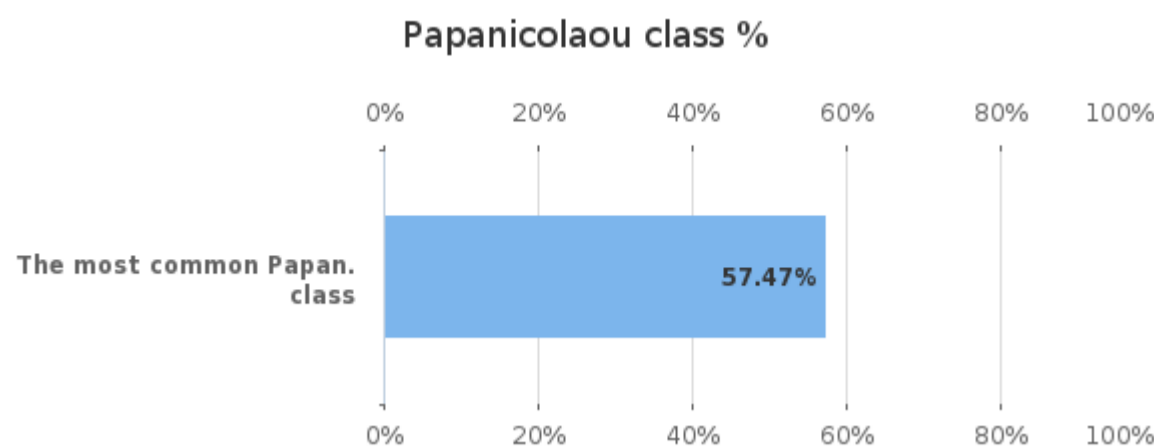
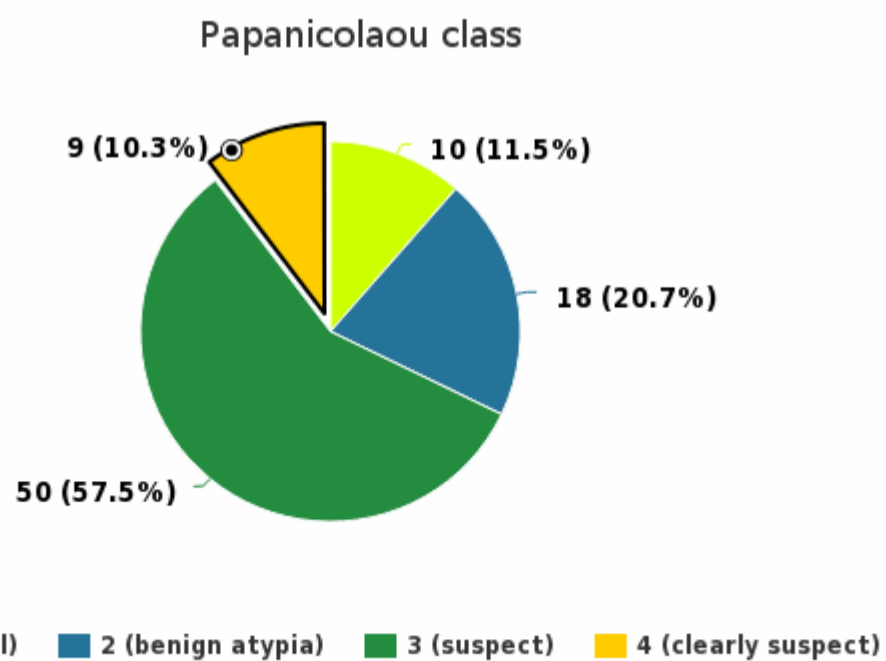




Specific diagnosis	n
Adenocarcinoma in situ, AIS	2
Atrophic vaginitis	1
Atypical glandular cells of undetermined significance, AGC-NOS	21
Atypical glandular cells, favour neoplastic, AGC-FN	8
Atypical glandular endocervical cells of undetermined significance, AGC-NOS	2
Atypical glandular endocervical cells, favour neoplastic, AGC-FN	4
Atypical glandular endometrial cells of undetermined significance, AGC-NOS	9
Atypical glandular endometrial cells, favour neoplastic, AGC-FN	13
Atypical squamous cells, cannot exclude HSIL, ASC-H	29
Atypical squamous cells of undetermined significance, ASC-US	4
Benign endometrium	2
Cervical adenocarcinoma	2
Endometrial adenocarcinoma	9
High grade SIL (CIN2, moderate dysplasia, CIN3, severe dysplasia, CIS)	14
Inflammation/regeneration	2
Low grade SIL (CIN1, slight dysplasia, HPV)	2
Negative for intraepithelial lesion and malignancy, NILM	1
Other malignant neoplasm	2
Radiation change	1
Squamous cell carcinoma, also suspicion	11
Total	139

Agreement percentage of the responses	%
The most common diagnosis	20.86

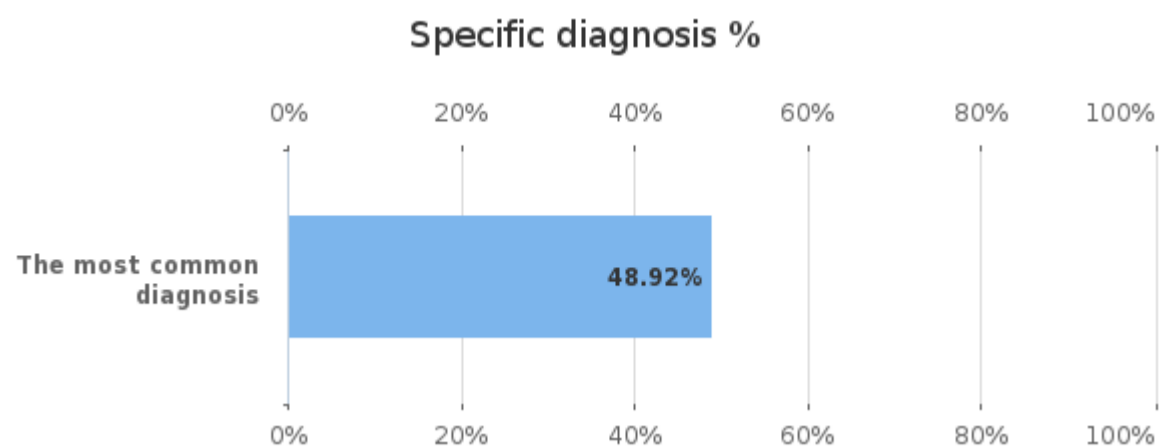
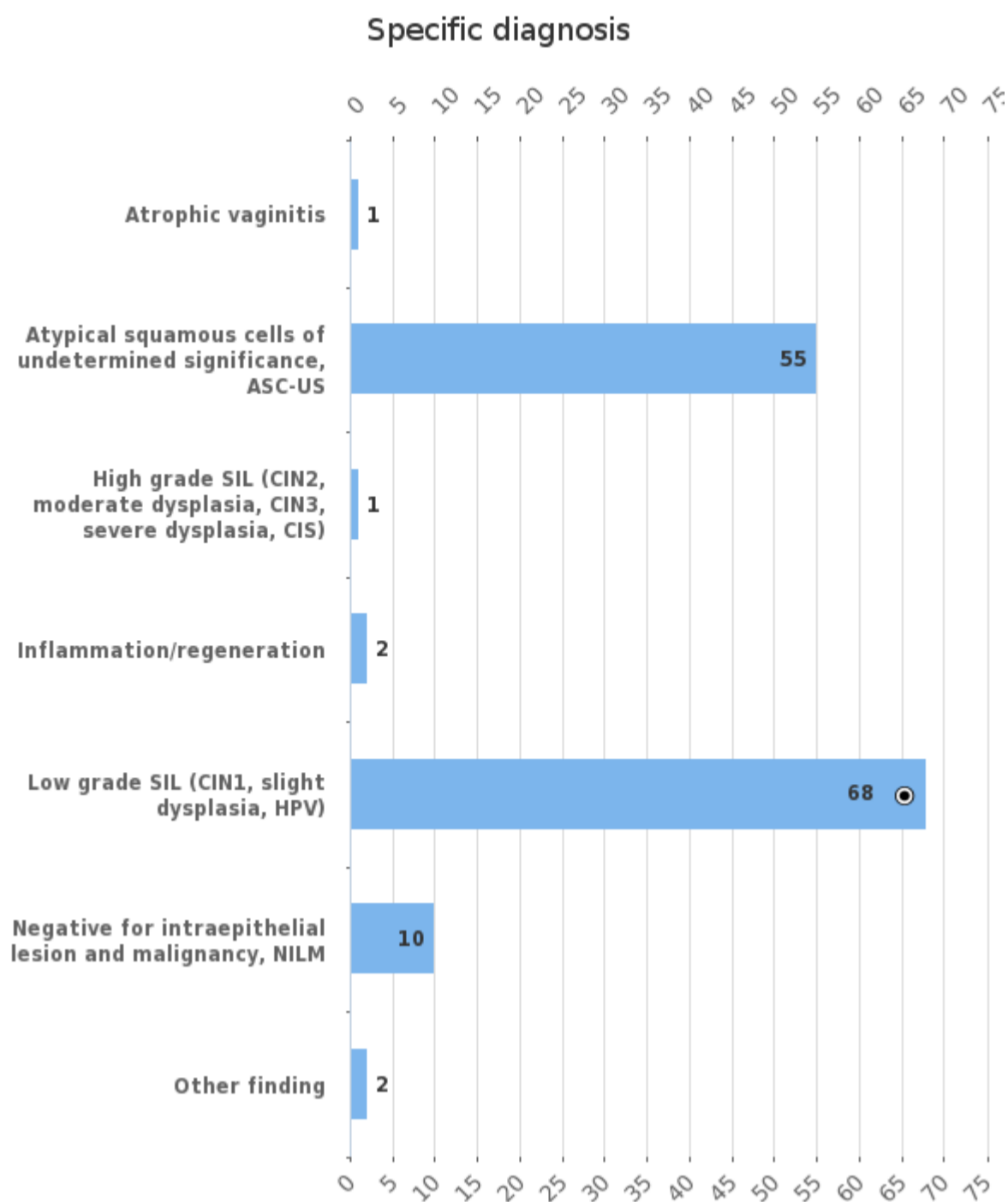
Sample S003 | Papanicolaou class



Papanicolaou class	n
1 (normal)	10
2 (benign atypia)	18
3 (suspect)	50
4 (clearly suspect)	9
Total	87

Agreement percentage of the responses	%
The most common Papan. class	57.47

Sample S003 | Specific diagnosis

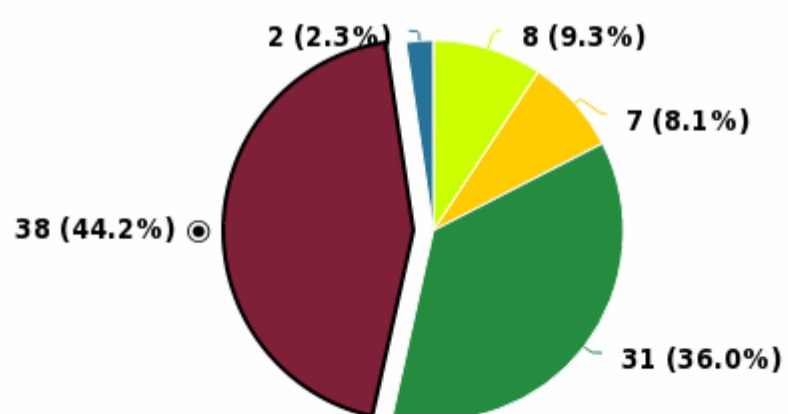


Specific diagnosis	n
Atrophic vaginitis	1
Atypical squamous cells of undetermined significance, ASC-US	55
High grade SIL (CIN2, moderate dysplasia, CIN3, severe dysplasia, CIS)	1
Inflammation/regeneration	2
Low grade SIL (CIN1, slight dysplasia, HPV)	68
Negative for intraepithelial lesion and malignancy, NILM	10
Other finding	2
Total	139

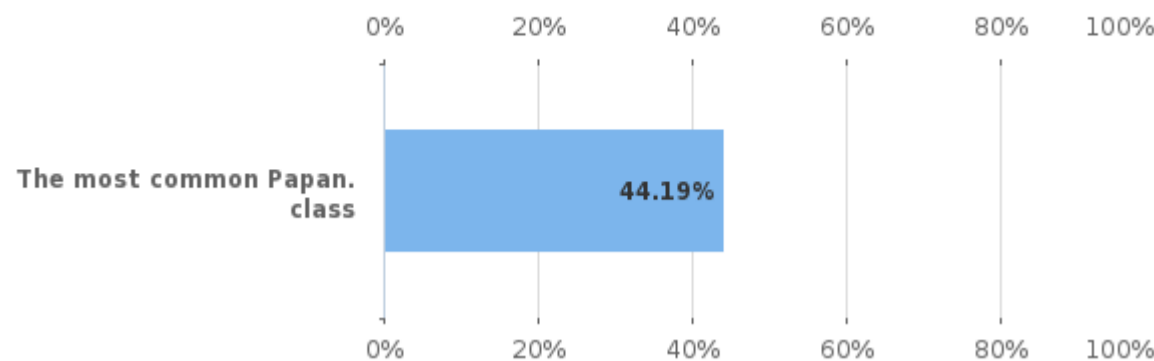
Agreement percentage of the responses	%
The most common diagnosis	48.92

Sample S004 | Papanicolaou class

Papanicolaou class



Papanicolaou class %

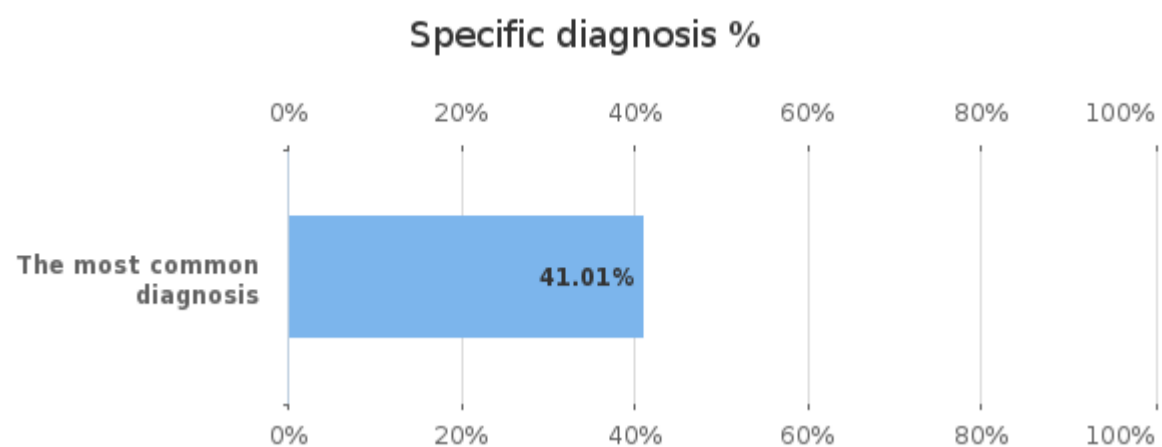
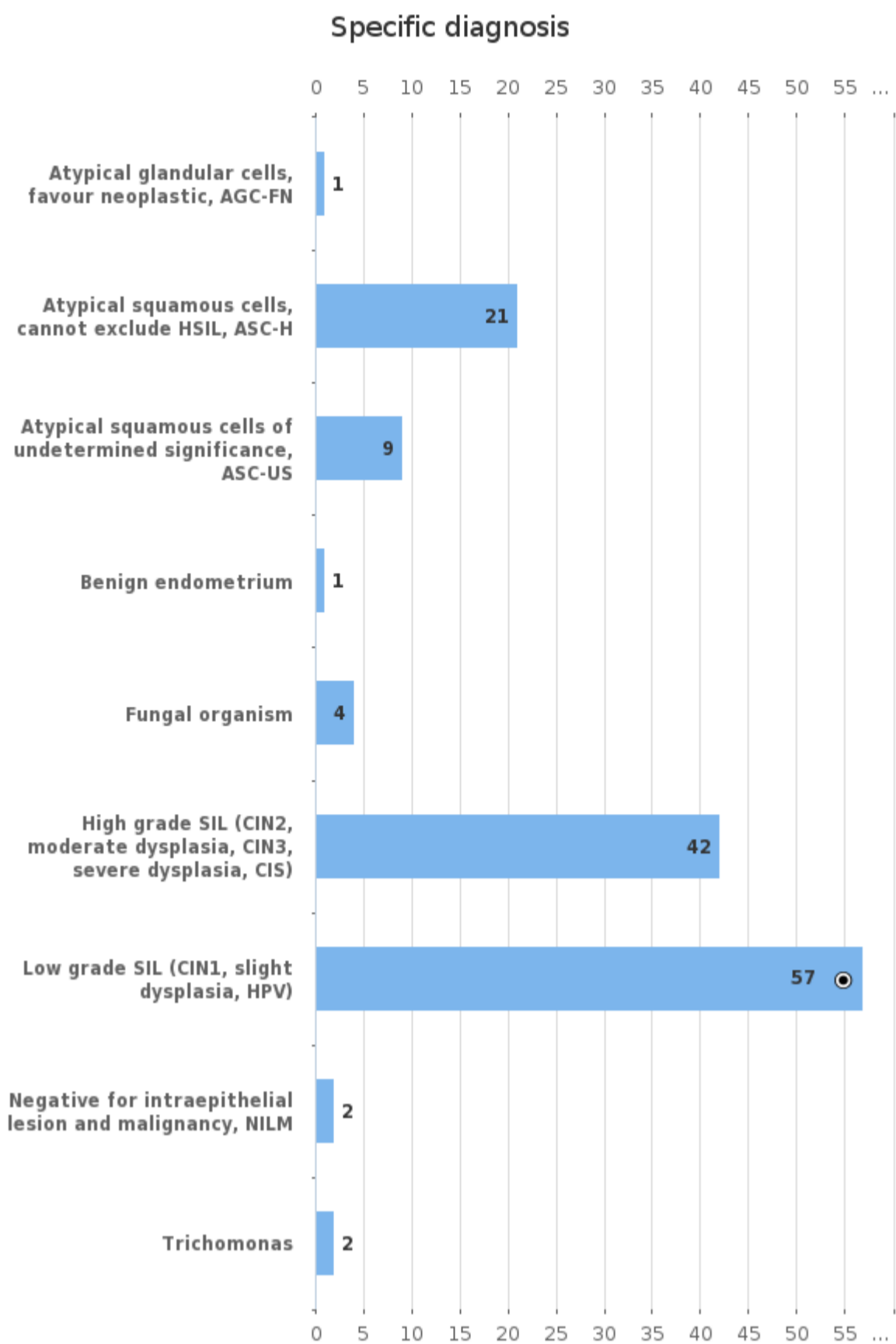


■ 1 (normal)
 ■ 2 (benign atypia)
 ■ 3 (suspect)
 ■ 4 (clearly suspect)
 ■ 5 (malignant)

Papanicolaou class	n
1 (normal)	8
2 (benign atypia)	7
3 (suspect)	31
4 (clearly suspect)	38
5 (malignant)	2
Total	86

Agreement percentage of the responses	%
The most common Papan. class	44.19

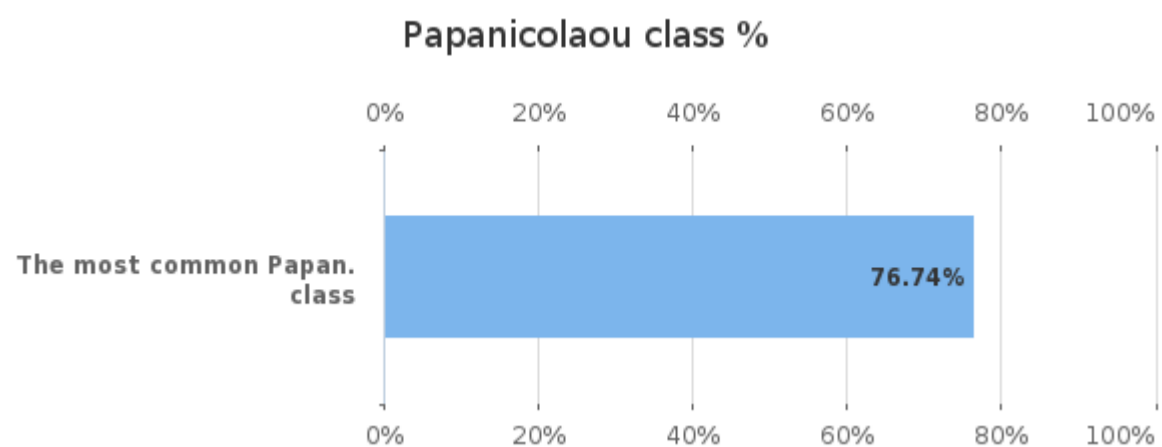
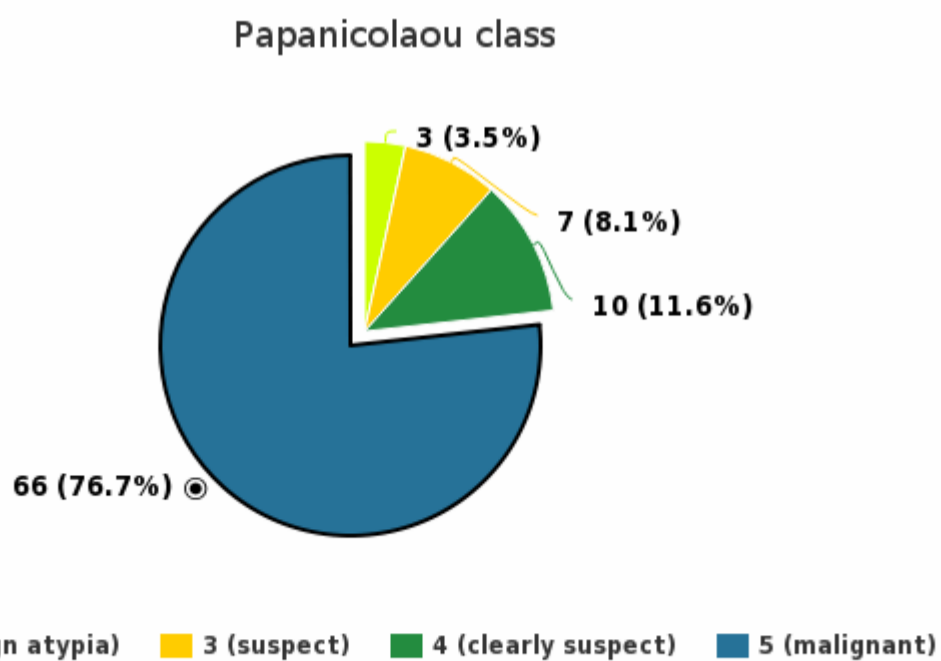
Sample S004 | Specific diagnosis



Specific diagnosis	n
Atypical glandular cells, favour neoplastic, AGC-FN	1
Atypical squamous cells, cannot exclude HSIL, ASC-H	21
Atypical squamous cells of undetermined significance, ASC-US	9
Benign endometrium	1
Fungal organism	4
High grade SIL (CIN2, moderate dysplasia, CIN3, severe dysplasia, CIS)	42
Low grade SIL (CIN1, slight dysplasia, HPV)	57
Negative for intraepithelial lesion and malignancy, NILM	2
Trichomonas	2
Total	139

Agreement percentage of the responses	%
The most common diagnosis	41.01

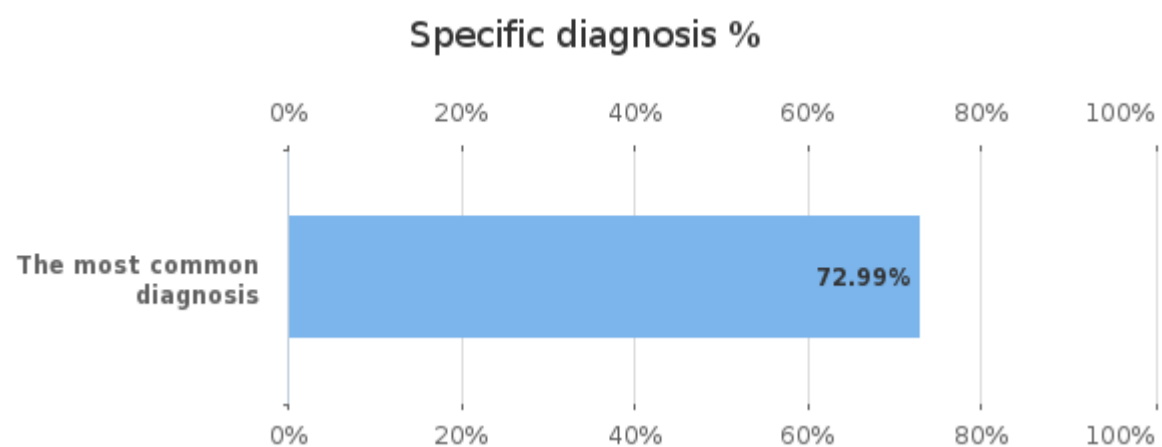
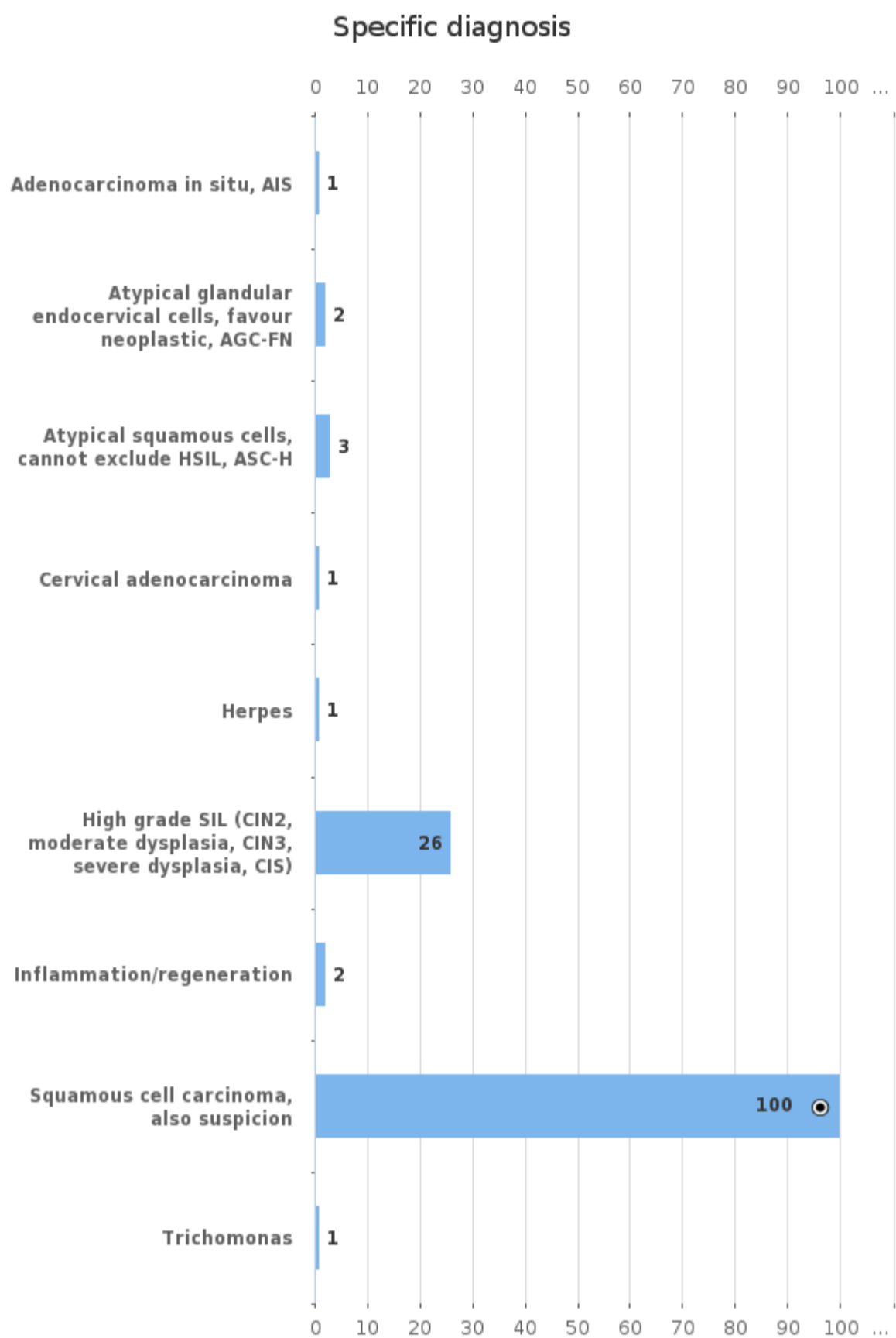
Sample S005 | Papanicolaou class



Papanicolaou class	n
2 (benign atypia)	3
3 (suspect)	7
4 (clearly suspect)	10
5 (malignant)	66
Total	86

Agreement percentage of the responses	%
The most common Papan. class	76.74

Sample S005 | Specific diagnosis

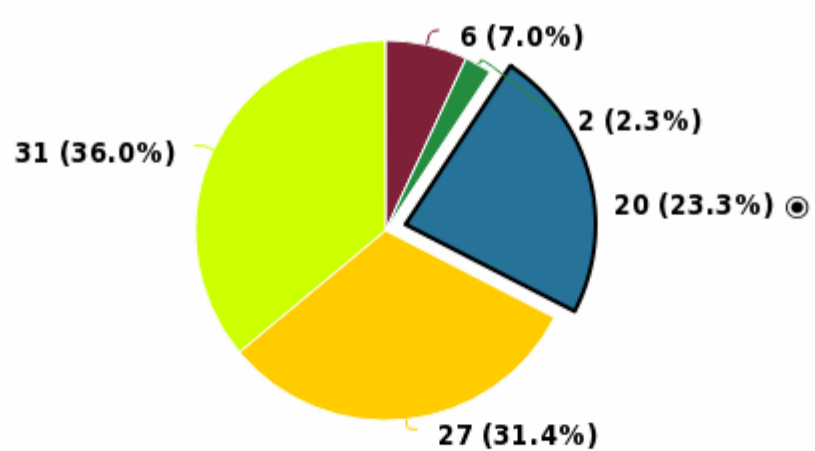


Specific diagnosis	n
Adenocarcinoma in situ, AIS	1
Atypical glandular endocervical cells, favour neoplastic, AGC-FN	2
Atypical squamous cells, cannot exclude HSIL, ASC-H	3
Cervical adenocarcinoma	1
Herpes	1
High grade SIL (CIN2, moderate dysplasia, CIN3, severe dysplasia, CIS)	26
Inflammation/regeneration	2
Squamous cell carcinoma, also suspicion	100
Trichomonas	1
Total	137

Agreement percentage of the responses	%
The most common diagnosis	72.99

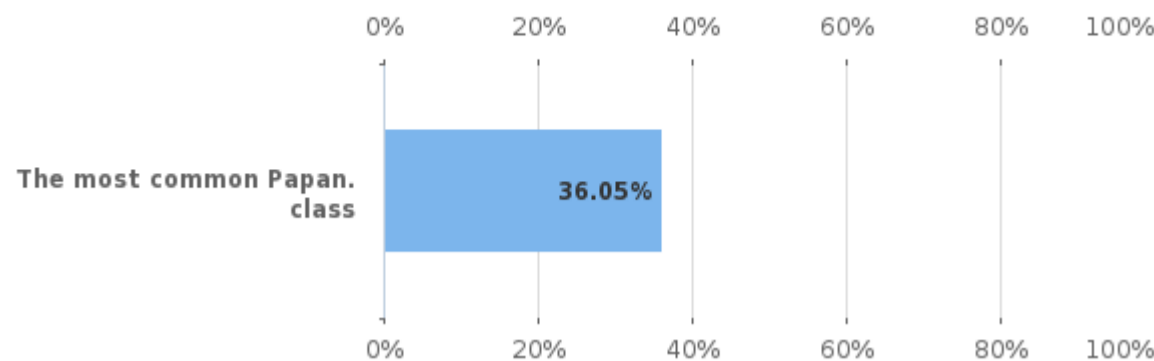
Sample S006 | Papanicolaou class

Papanicolaou class



1 (normal) 2 (benign atypia) 3 (suspect) 4 (clearly suspect)
5 (malignant)

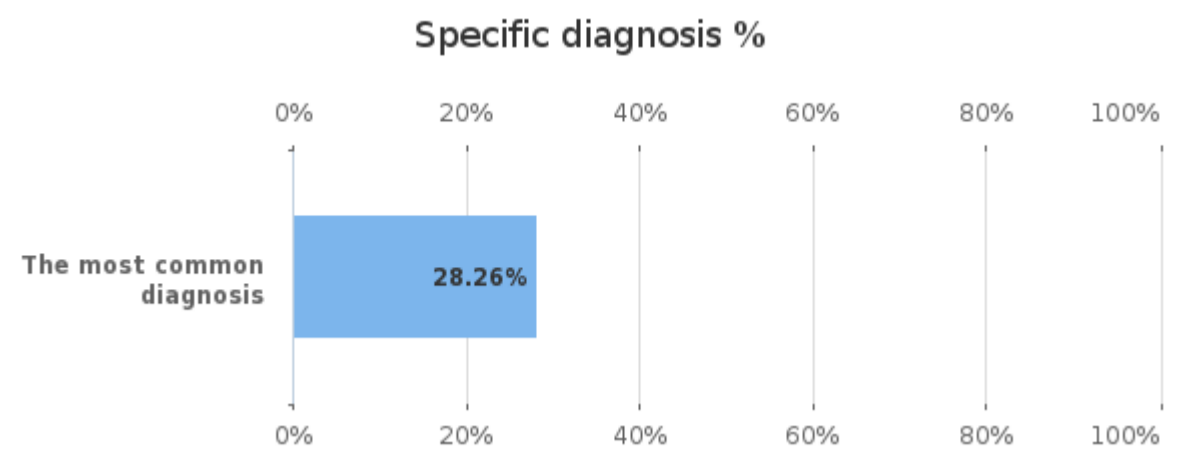
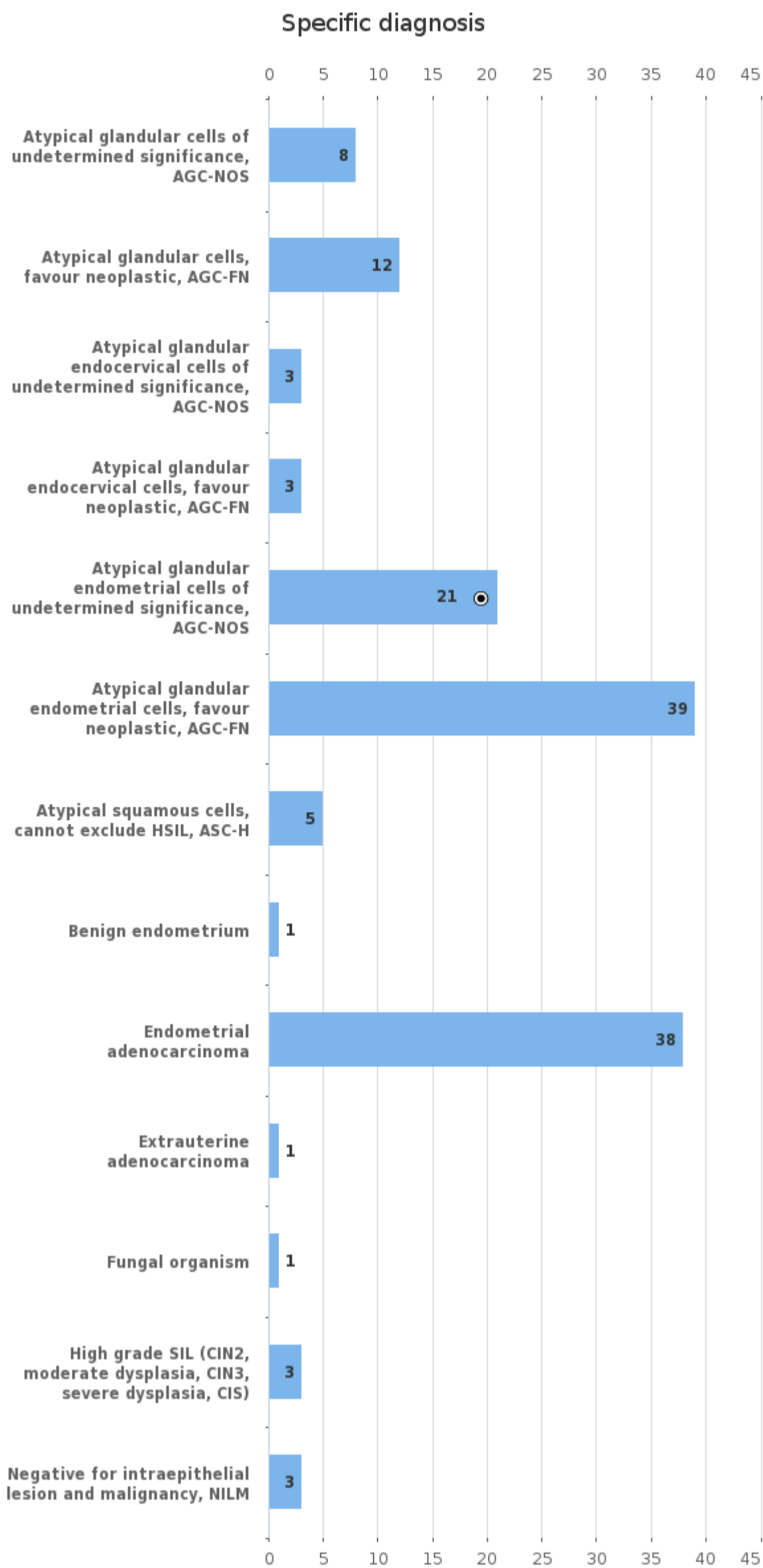
Papanicolaou class %



Papanicolaou class	n
1 (normal)	6
2 (benign atypia)	2
3 (suspect)	20
4 (clearly suspect)	27
5 (malignant)	31
Total	86

Agreement percentage of the responses	%
The most common Papan. class	36.05

Sample S006 | Specific diagnosis



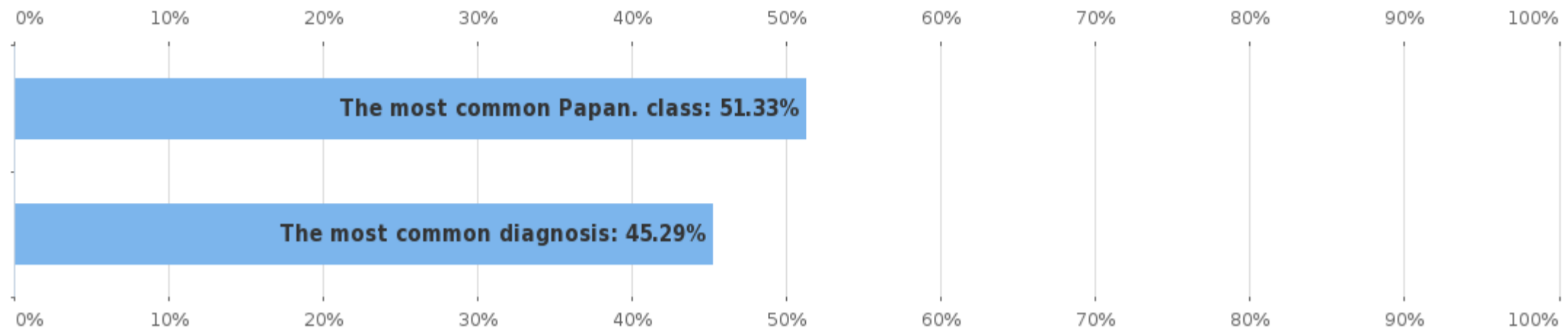
Specific diagnosis	n
Atypical glandular cells of undetermined significance, AGC-NOS	8
Atypical glandular cells, favour neoplastic, AGC-FN	12
Atypical glandular endocervical cells of undetermined significance, AGC-NOS	3
Atypical glandular endocervical cells, favour neoplastic, AGC-FN	3
Atypical glandular endometrial cells of undetermined significance, AGC-NOS	21
Atypical glandular endometrial cells, favour neoplastic, AGC-FN	39
Atypical squamous cells, cannot exclude HSIL, ASC-H	5
Benign endometrium	1
Endometrial adenocarcinoma	38
Extrauterine adenocarcinoma	1
Fungal organism	1
High grade SIL (CIN2, moderate dysplasia, CIN3, severe dysplasia, CIS)	3
Negative for intraepithelial lesion and malignancy, NILM	3

Agreement percentage of the responses	%
The most common diagnosis	28.26

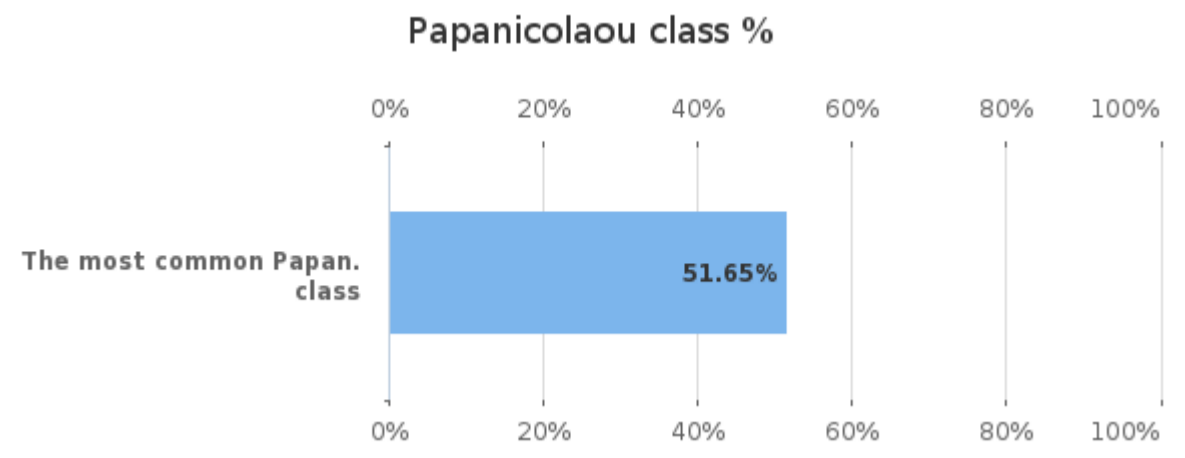
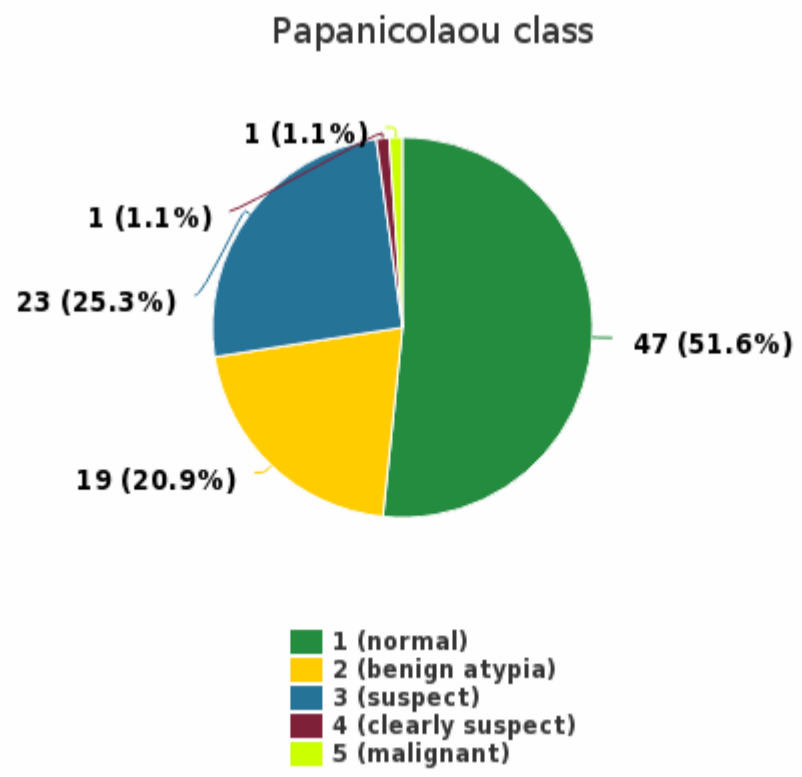
Negative for intraepithelial lesion and malignancy, NILM	3
Total	138

Round	No of participants	No of responded participants	Response percentage %
Gynaecological cytology (liquid based), virtual microscopy, May, 1-2022	121	111	91.74%

Agreement percentage of the responses



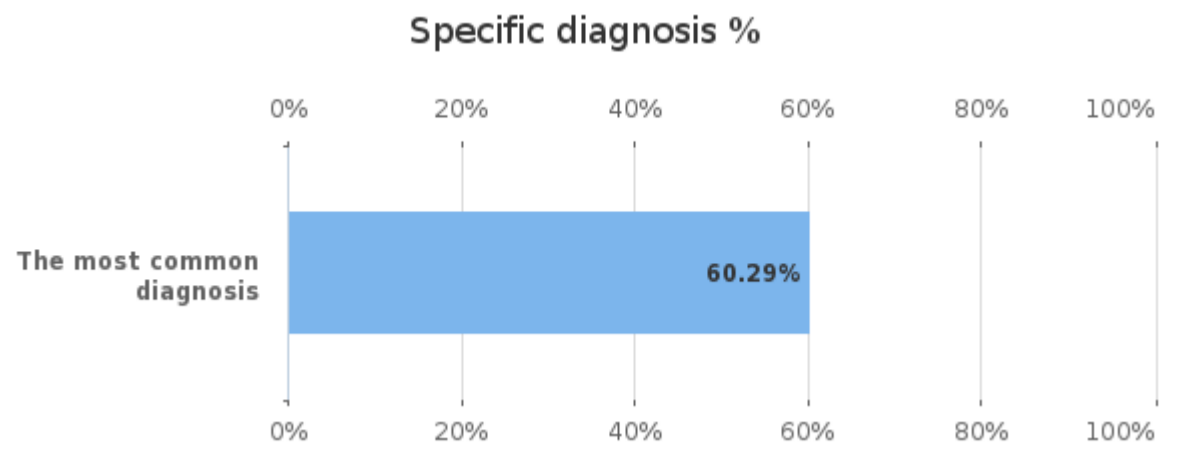
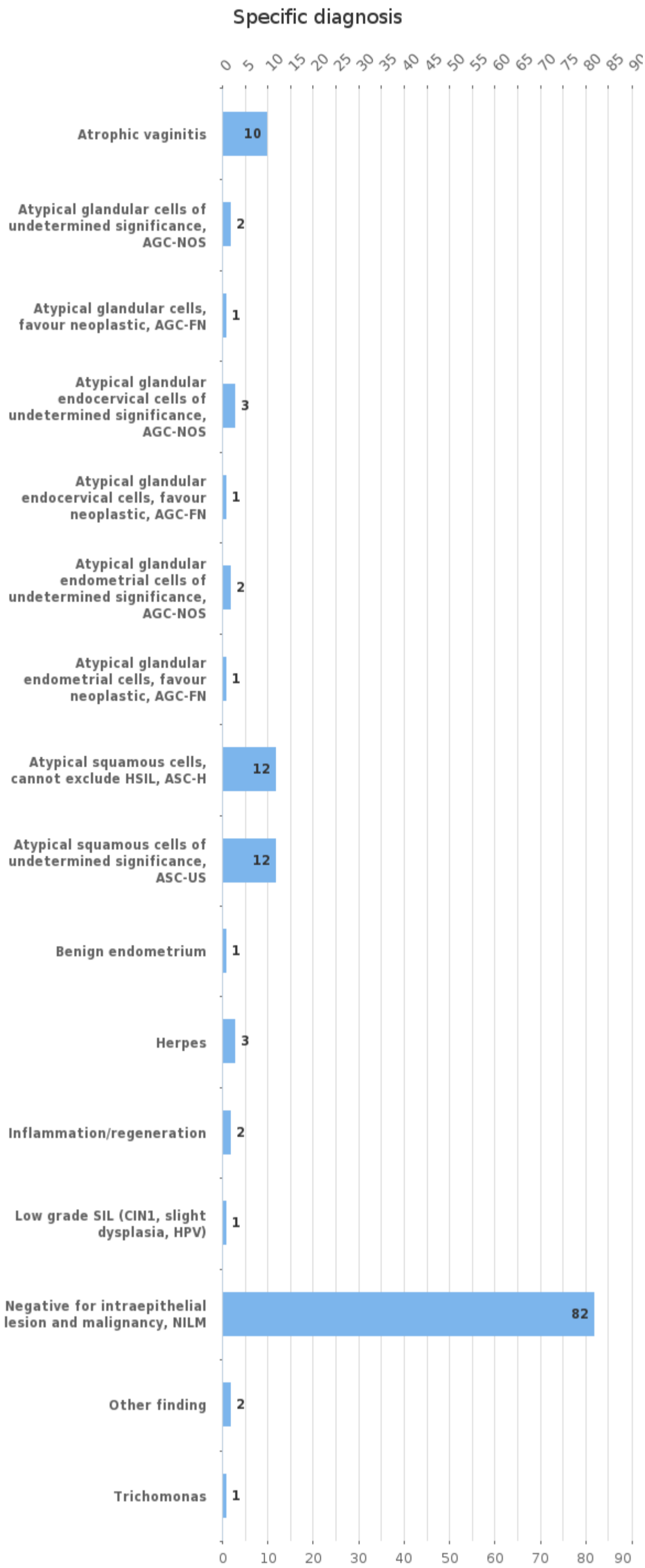
Sample S001 | Papanicolaou class



Papanicolaou class	n
1 (normal)	47
2 (benign atypia)	19
3 (suspect)	23
4 (clearly suspect)	1
5 (malignant)	1
Total	91

Agreement percentage of the responses	%
The most common Papan. class	51.65

Sample S001 | Specific diagnosis

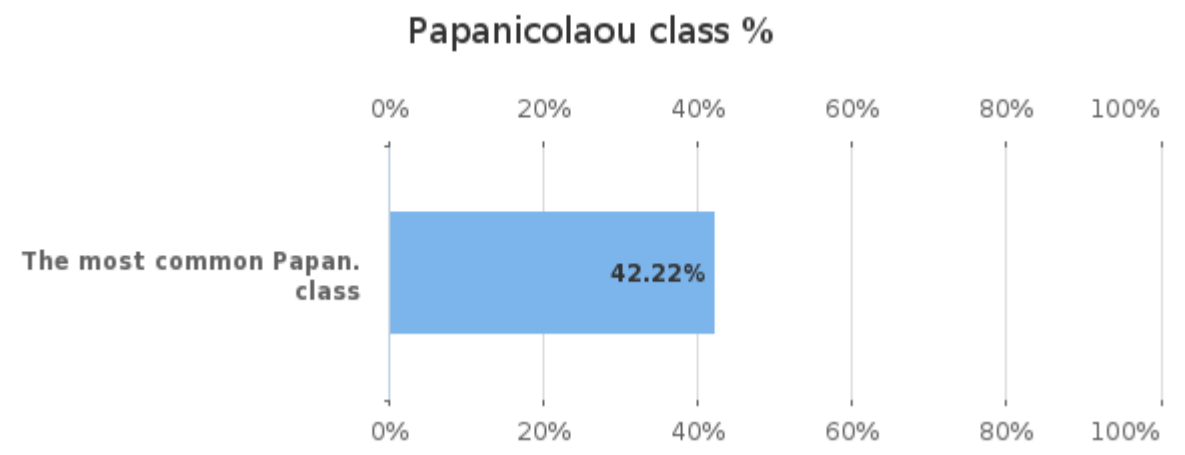
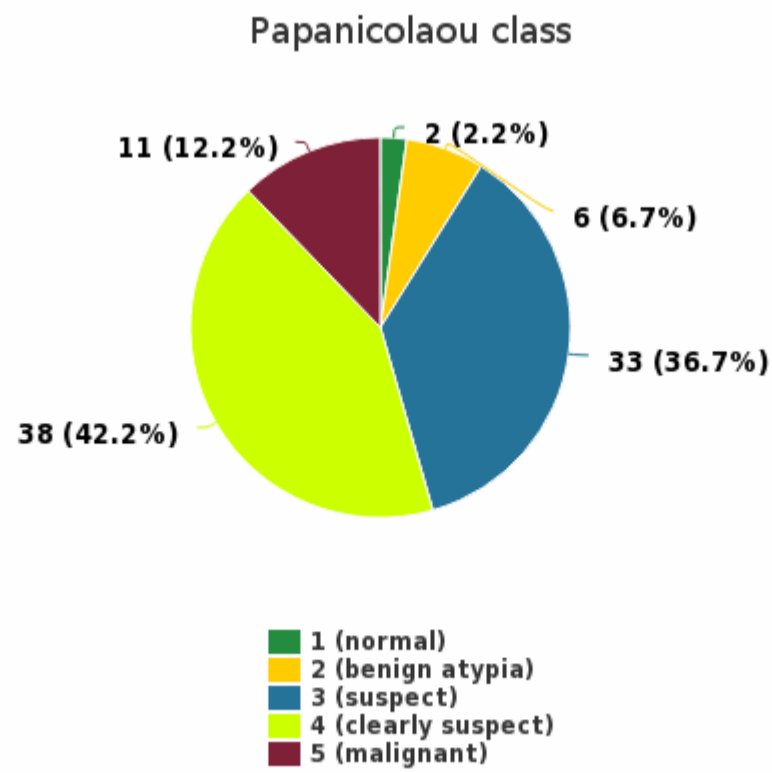


Specific diagnosis	n
Atrophic vaginitis	10
Atypical glandular cells of undetermined significance, AGC-NOS	2
Atypical glandular cells, favour neoplastic, AGC-FN	1

Agreement percentage of the responses	%
The most common diagnosis	60.29

Atypical glandular endocervical cells of undetermined significance, AGC-NOS	3
Atypical glandular endocervical cells, favour neoplastic, AGC-FN	1
Atypical glandular endometrial cells of undetermined significance, AGC-NOS	2
Atypical glandular endometrial cells, favour neoplastic, AGC-FN	1
Atypical squamous cells, cannot exclude HSIL, ASC-H	12
Atypical squamous cells of undetermined significance, ASC-US	12
Benign endometrium	1
Herpes	3
Inflammation/regeneration	2
Low grade SIL (CIN1, slight dysplasia, HPV)	1
Negative for intraepithelial lesion and malignancy, NILM	82
Other finding	2
Trichomonas	1
Total	136

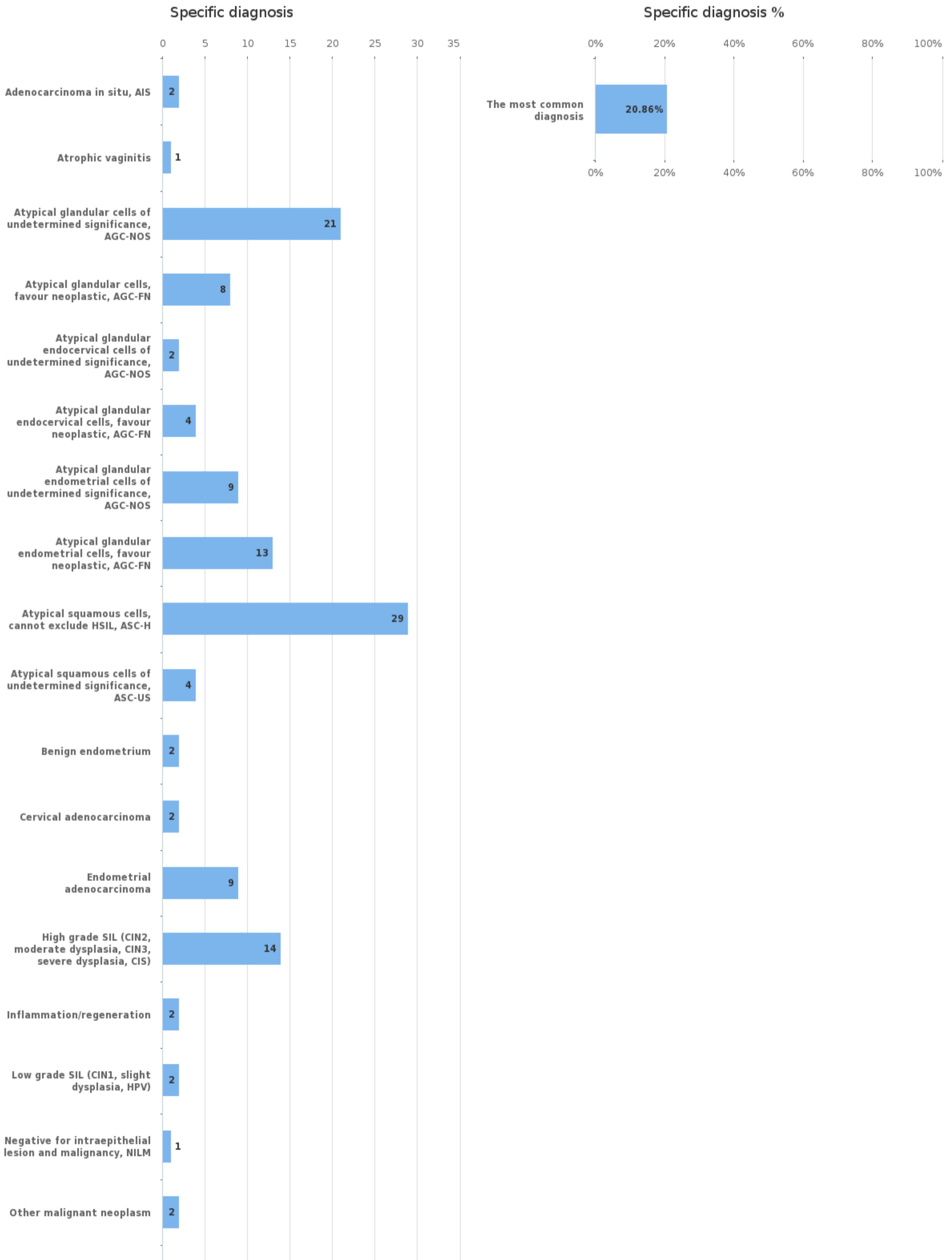
Sample S002 | Papanicolaou class

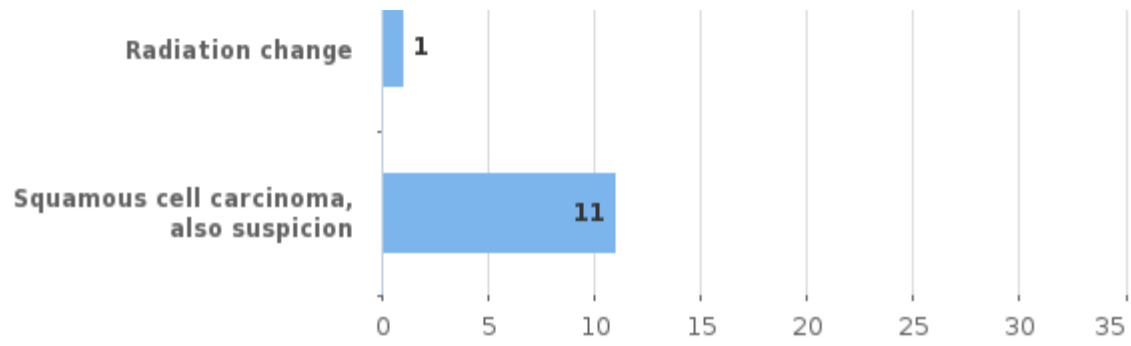


Papanicolaou class	n
1 (normal)	2
2 (benign atypia)	6
3 (suspect)	33
4 (clearly suspect)	38
5 (malignant)	11
Total	90

Agreement percentage of the responses	%
The most common Papan. class	42.22

Sample S002 | Specific diagnosis

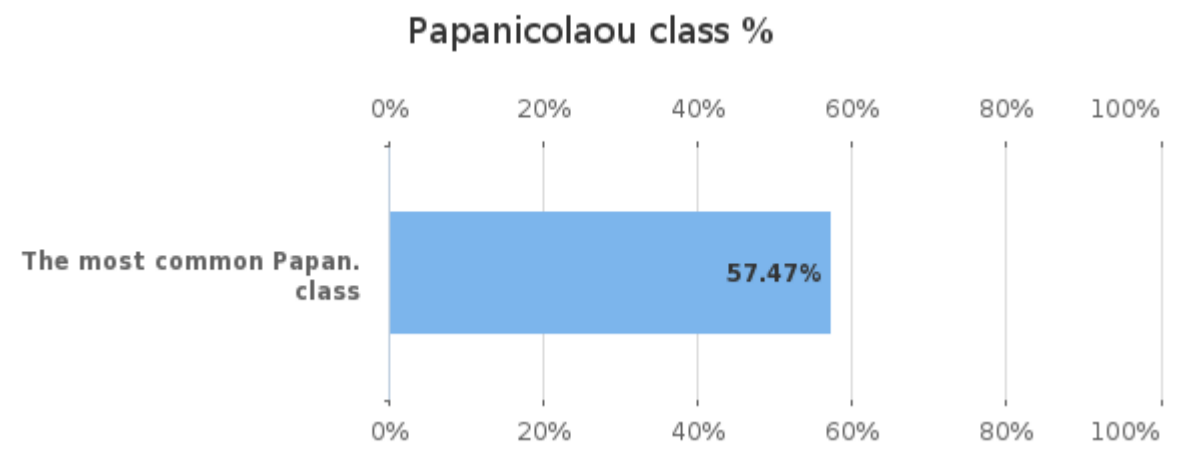
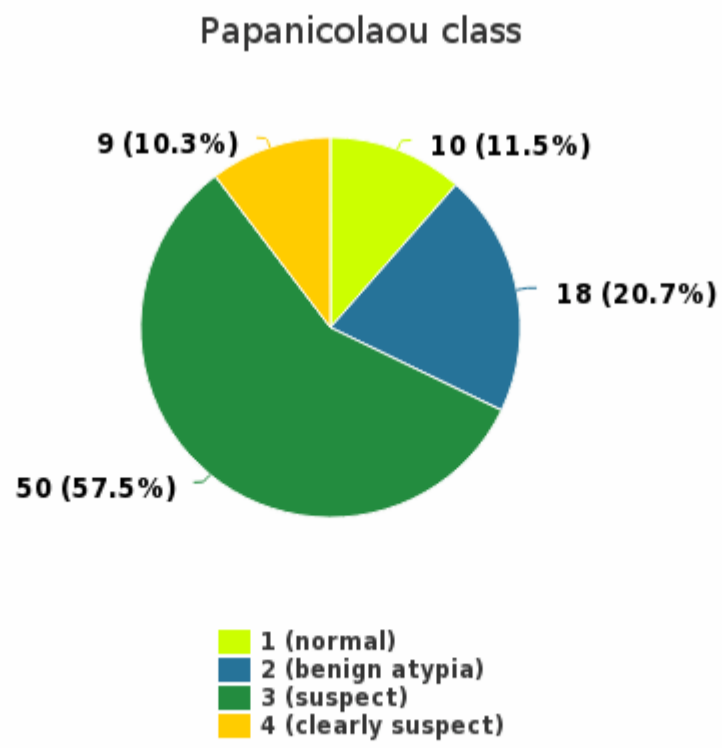




Specific diagnosis	n
Adenocarcinoma in situ, AIS	2
Atrophic vaginitis	1
Atypical glandular cells of undetermined significance, AGC-NOS	21
Atypical glandular cells, favour neoplastic, AGC-FN	8
Atypical glandular endocervical cells of undetermined significance, AGC-NOS	2
Atypical glandular endocervical cells, favour neoplastic, AGC-FN	4
Atypical glandular endometrial cells of undetermined significance, AGC-NOS	9
Atypical glandular endometrial cells, favour neoplastic, AGC-FN	13
Atypical squamous cells, cannot exclude HSIL, ASC-H	29
Atypical squamous cells of undetermined significance, ASC-US	4
Benign endometrium	2
Cervical adenocarcinoma	2
Endometrial adenocarcinoma	9
High grade SIL (CIN2, moderate dysplasia, CIN3, severe dysplasia, CIS)	14
Inflammation/regeneration	2
Low grade SIL (CIN1, slight dysplasia, HPV)	2
Negative for intraepithelial lesion and malignancy, NILM	1
Other malignant neoplasm	2
Radiation change	1
Squamous cell carcinoma, also suspicion	11
Total	139

Agreement percentage of the responses	%
The most common diagnosis	20.86

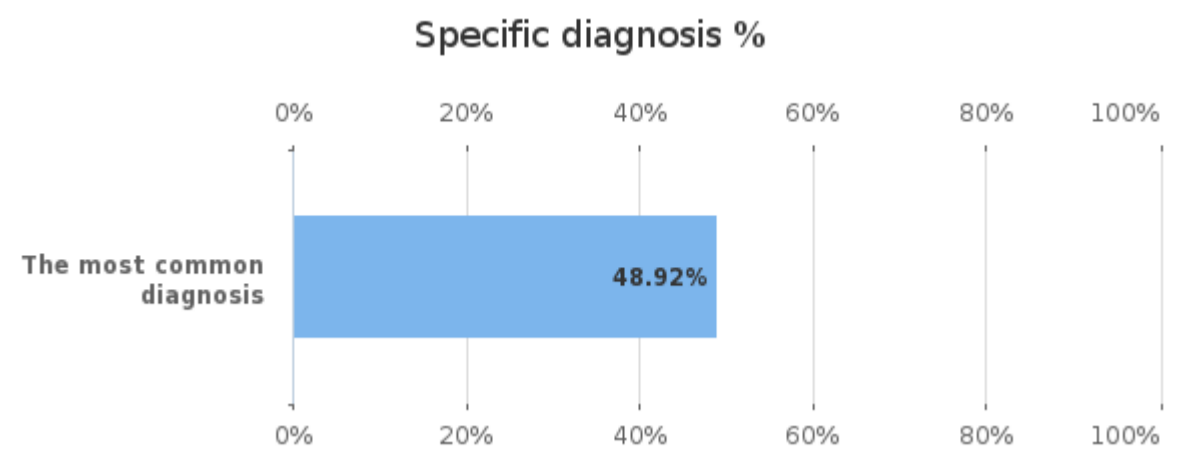
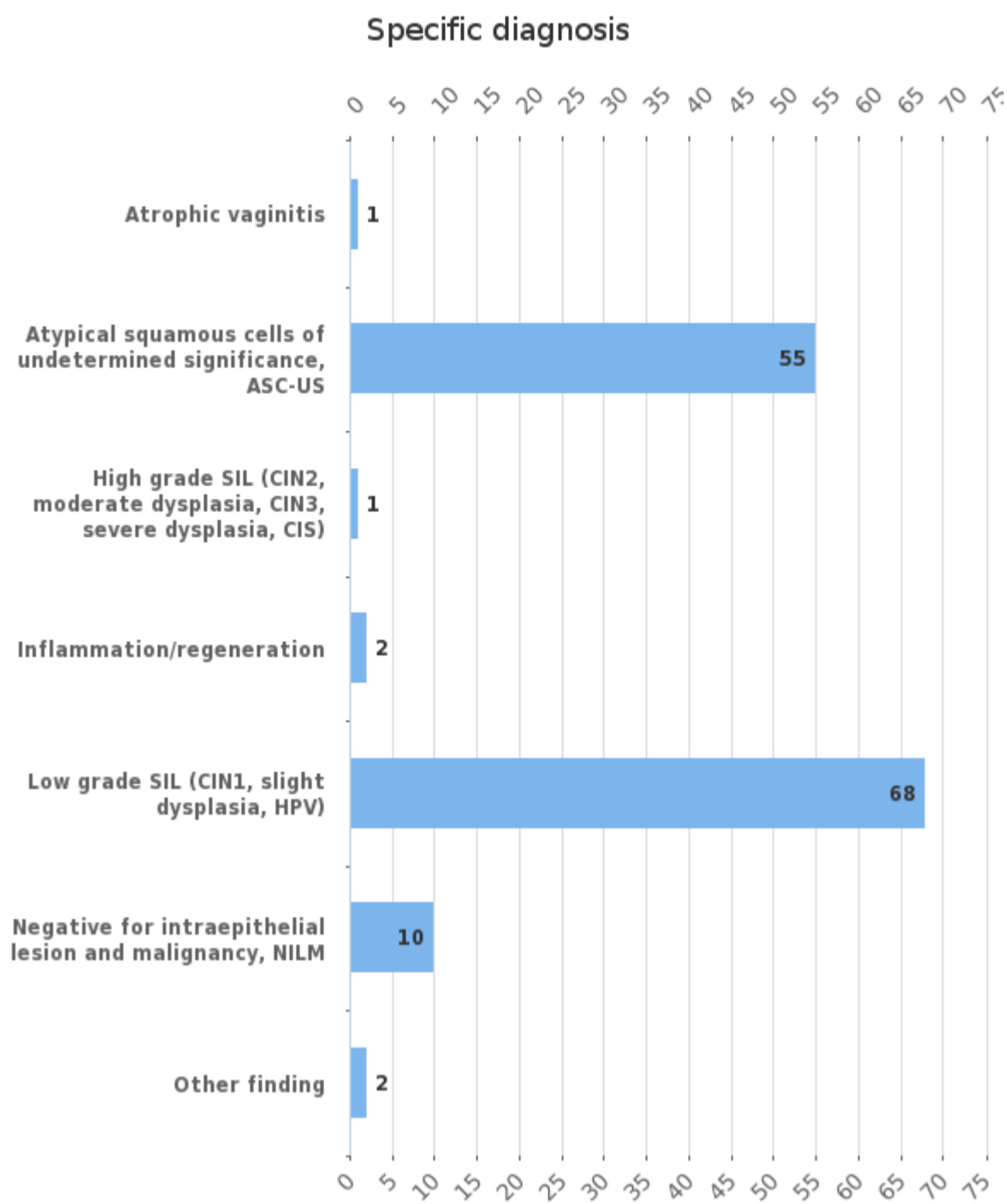
Sample S003 | Papanicolaou class



Papanicolaou class	n
1 (normal)	10
2 (benign atypia)	18
3 (suspect)	50
4 (clearly suspect)	9
Total	87

Agreement percentage of the responses	%
The most common Papan. class	57.47

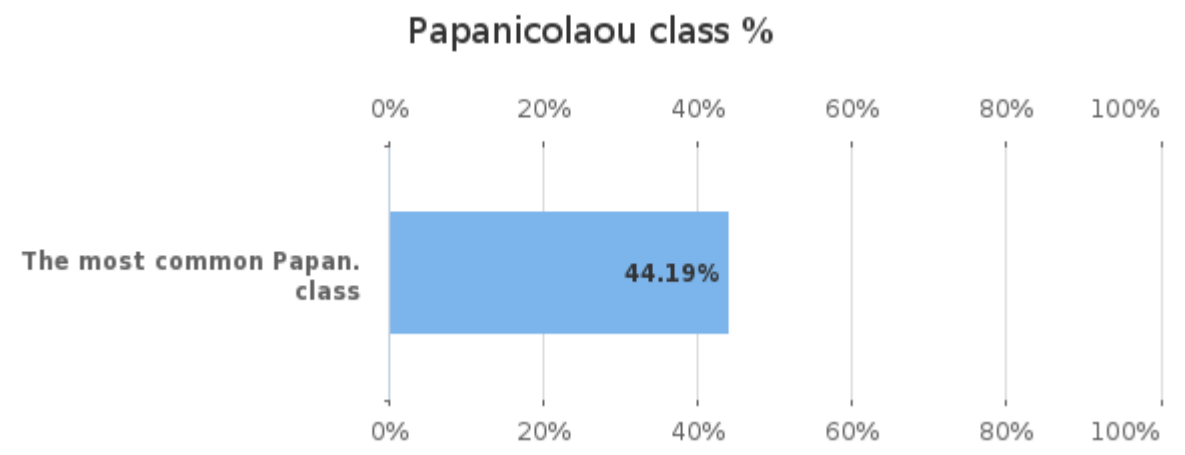
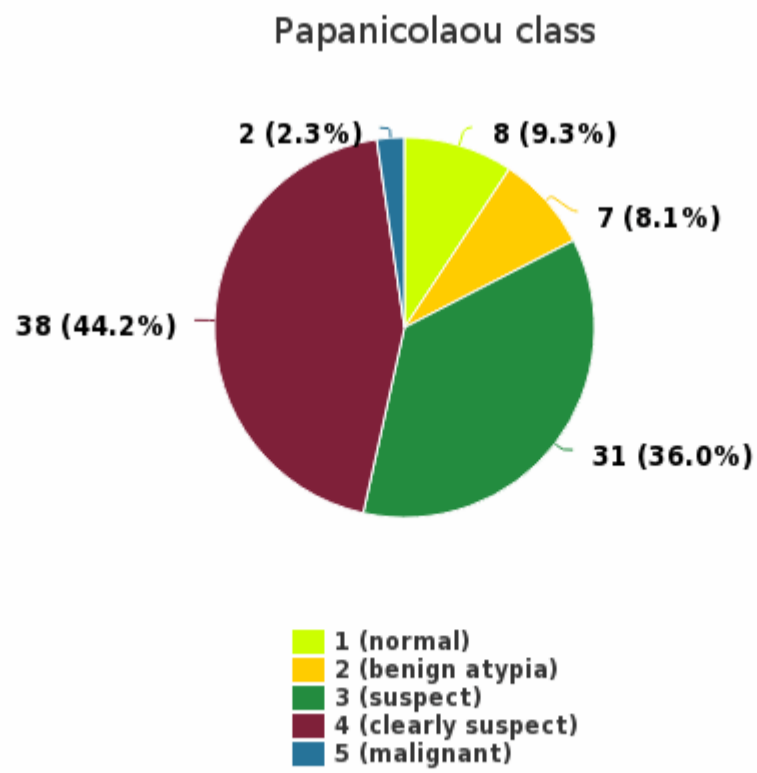
Sample S003 | Specific diagnosis



Specific diagnosis	n
Atrophic vaginitis	1
Atypical squamous cells of undetermined significance, ASC-US	55
High grade SIL (CIN2, moderate dysplasia, CIN3, severe dysplasia, CIS)	1
Inflammation/regeneration	2
Low grade SIL (CIN1, slight dysplasia, HPV)	68
Negative for intraepithelial lesion and malignancy, NILM	10
Other finding	2
Total	139

Agreement percentage of the responses	%
The most common diagnosis	48.92

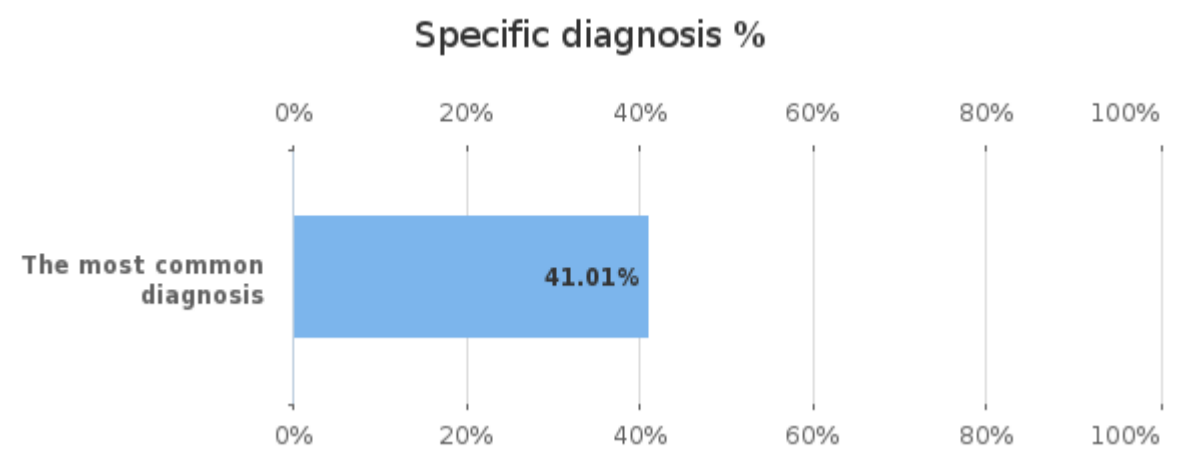
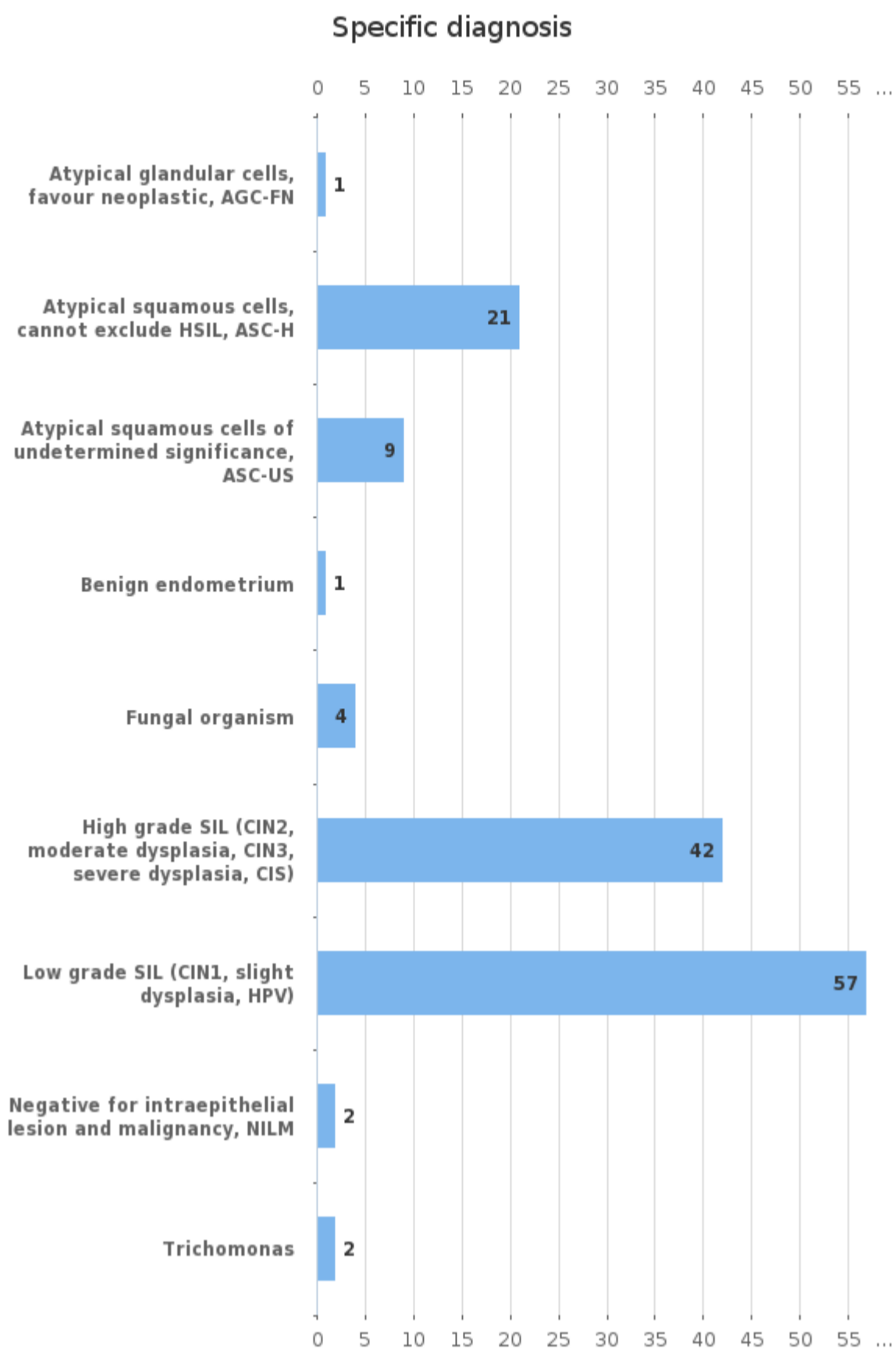
Sample S004 | Papanicolaou class



Papanicolaou class	n
1 (normal)	8
2 (benign atypia)	7
3 (suspect)	31
4 (clearly suspect)	38
5 (malignant)	2
Total	86

Agreement percentage of the responses	%
The most common Papan. class	44.19

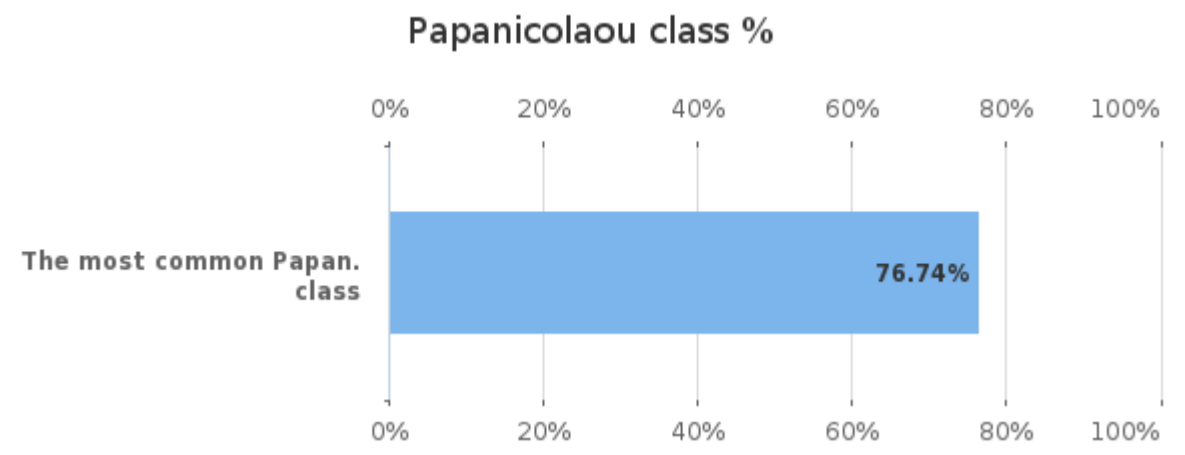
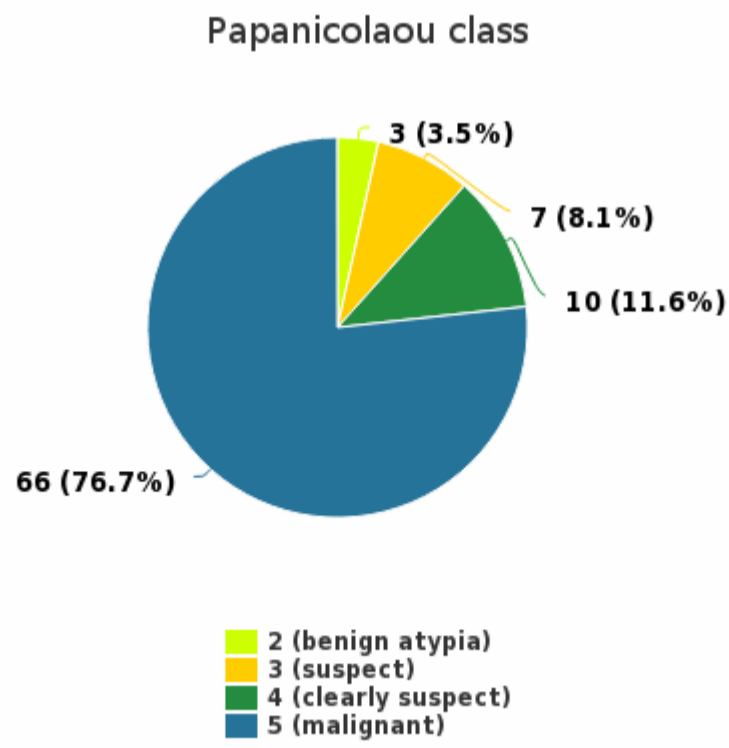
Sample S004 | Specific diagnosis



Specific diagnosis	n
Atypical glandular cells, favour neoplastic, AGC-FN	1
Atypical squamous cells, cannot exclude HSIL, ASC-H	21
Atypical squamous cells of undetermined significance, ASC-US	9
Benign endometrium	1
Fungal organism	4
High grade SIL (CIN2, moderate dysplasia, CIN3, severe dysplasia, CIS)	42
Low grade SIL (CIN1, slight dysplasia, HPV)	57
Negative for intraepithelial lesion and malignancy, NILM	2
Trichomonas	2
Total	139

Agreement percentage of the responses	%
The most common diagnosis	41.01

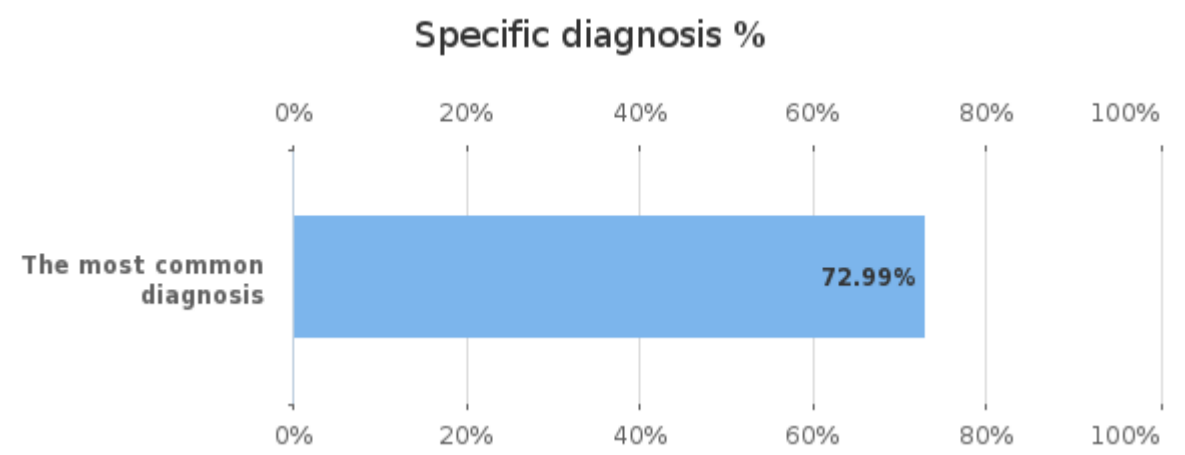
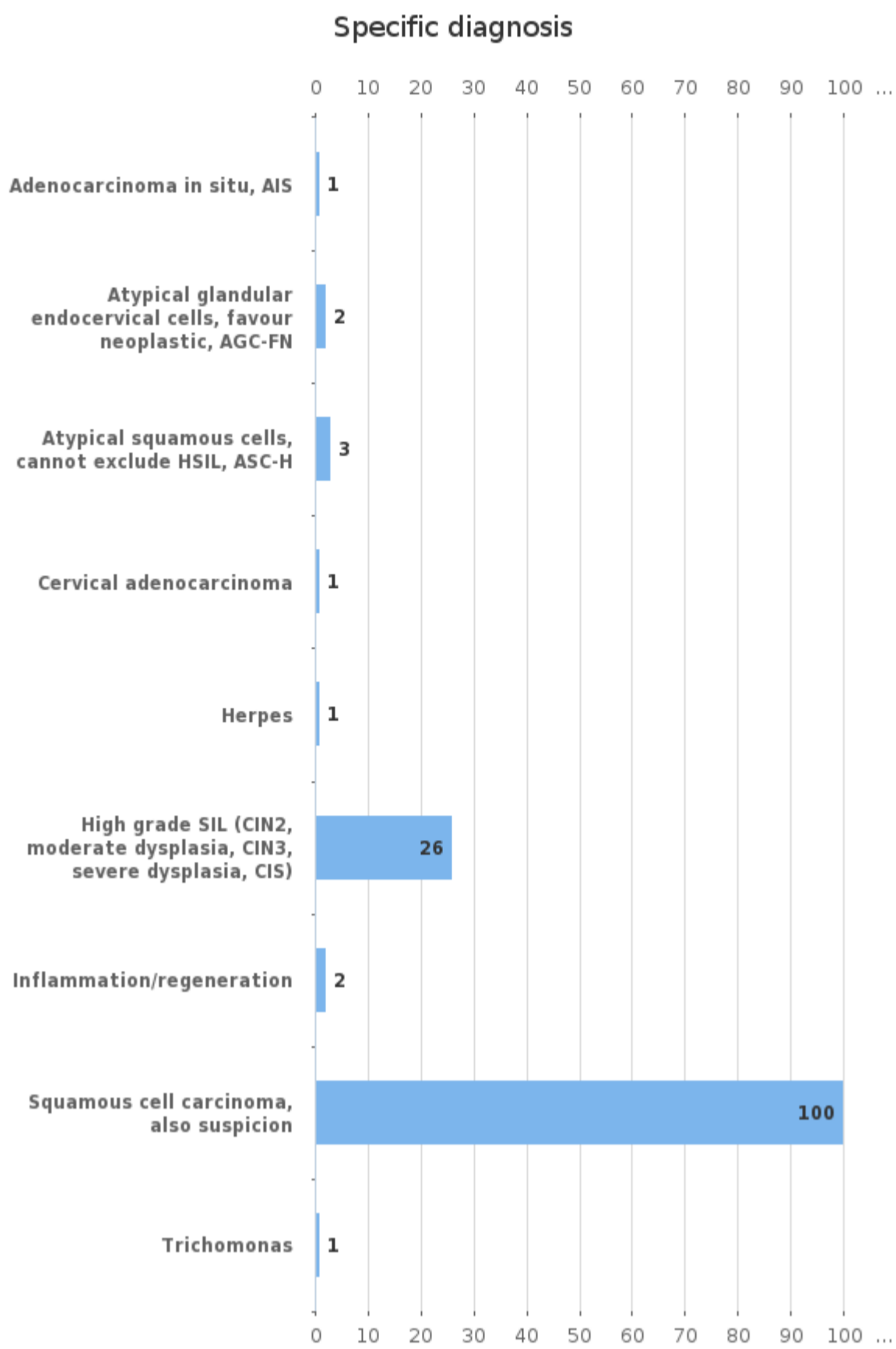
Sample S005 | Papanicolaou class



Papanicolaou class	n
2 (benign atypia)	3
3 (suspect)	7
4 (clearly suspect)	10
5 (malignant)	66
Total	86

Agreement percentage of the responses	%
The most common Papan. class	76.74

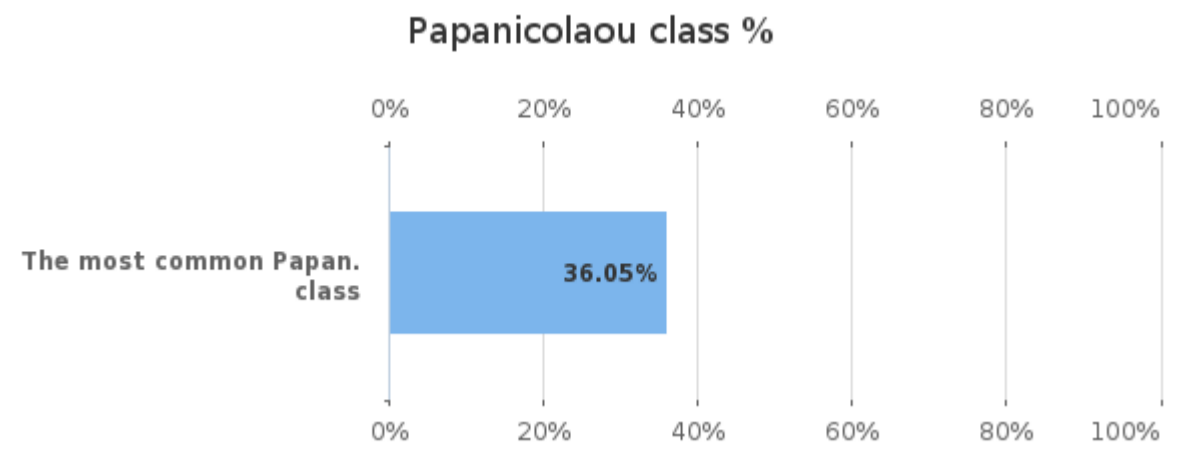
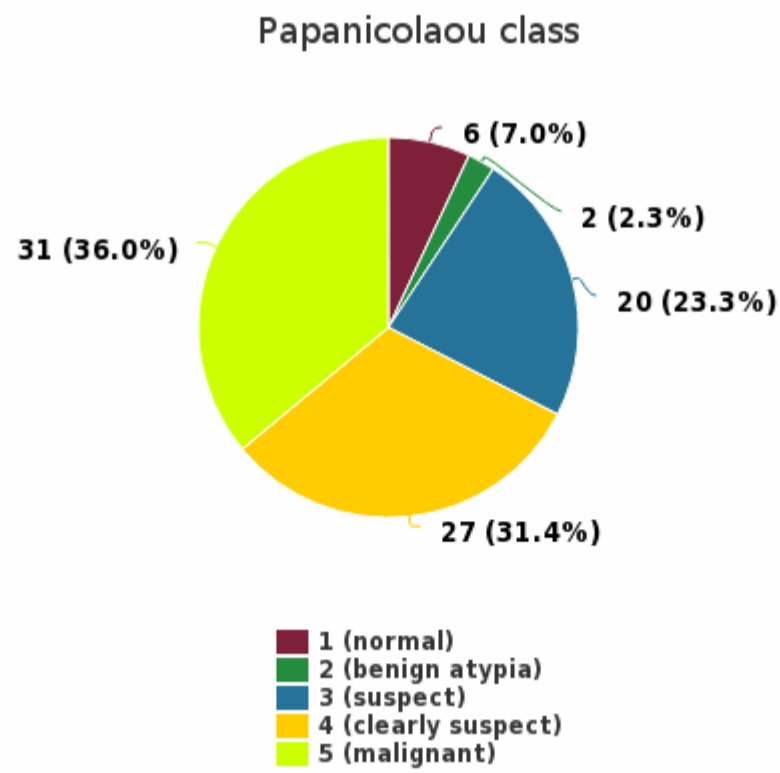
Sample S005 | Specific diagnosis



Specific diagnosis	n
Adenocarcinoma in situ, AIS	1
Atypical glandular endocervical cells, favour neoplastic, AGC-FN	2
Atypical squamous cells, cannot exclude HSIL, ASC-H	3
Cervical adenocarcinoma	1
Herpes	1
High grade SIL (CIN2, moderate dysplasia, CIN3, severe dysplasia, CIS)	26
Inflammation/regeneration	2
Squamous cell carcinoma, also suspicion	100
Trichomonas	1
Total	137

Agreement percentage of the responses	%
The most common diagnosis	72.99

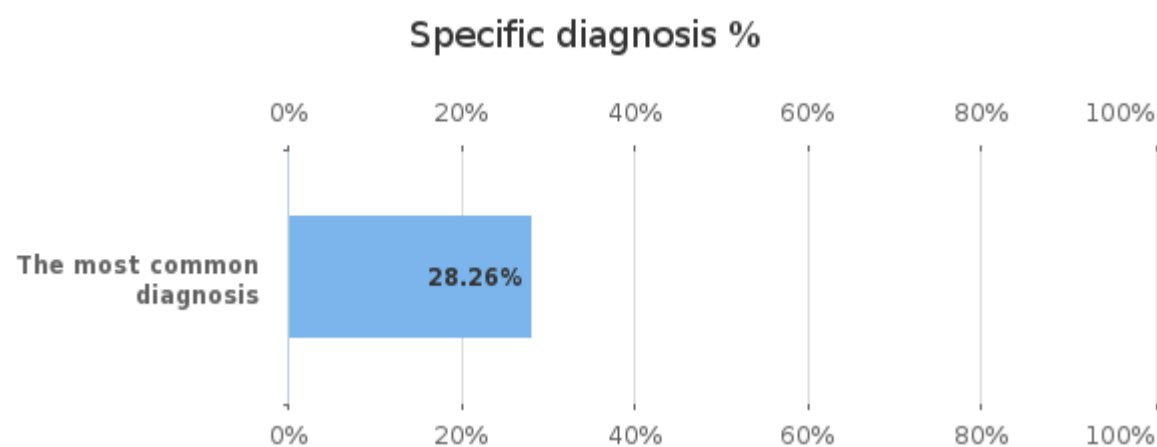
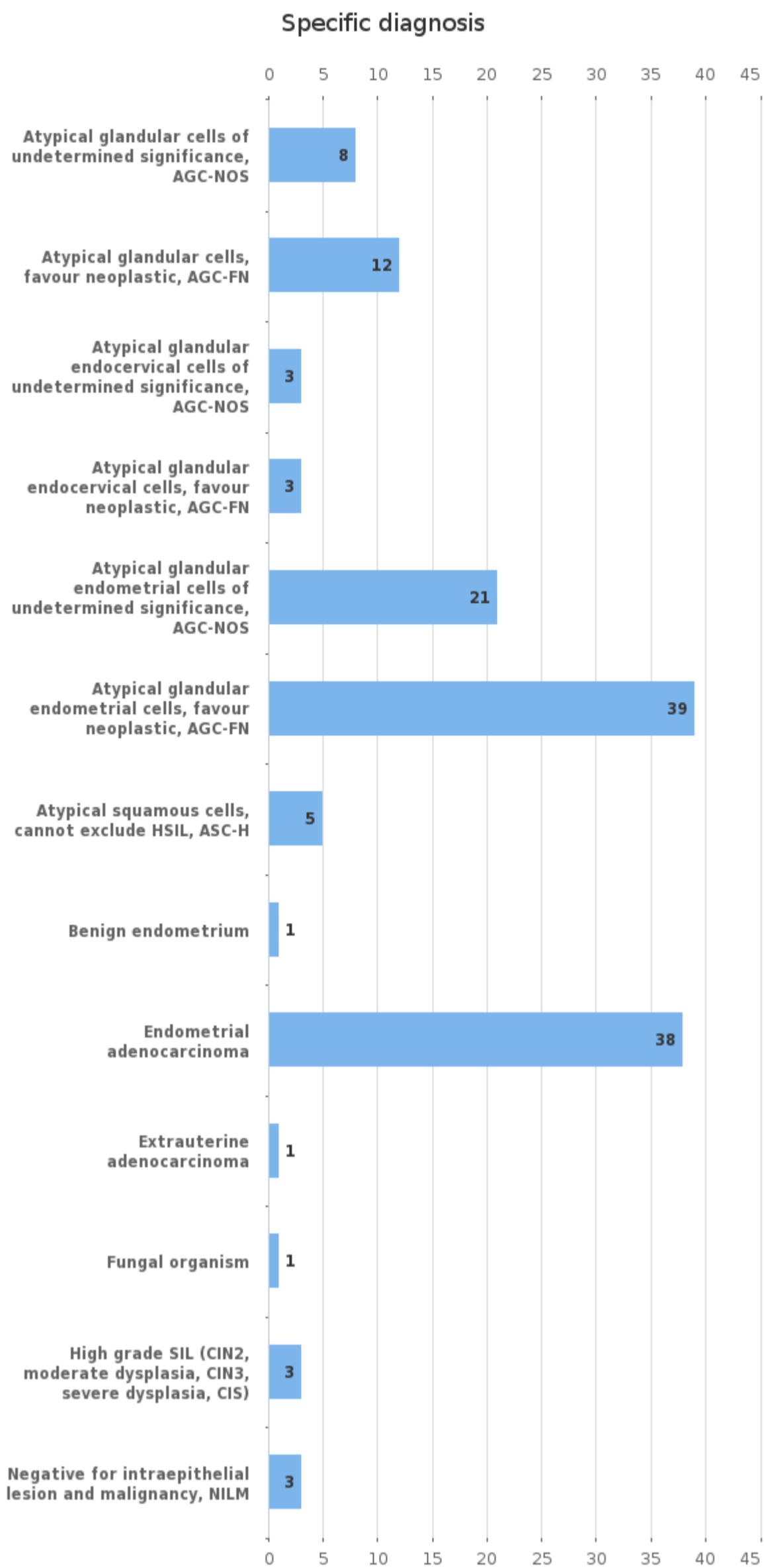
Sample S006 | Papanicolaou class



Papanicolaou class	n
1 (normal)	6
2 (benign atypia)	2
3 (suspect)	20
4 (clearly suspect)	27
5 (malignant)	31
Total	86

Agreement percentage of the responses	%
The most common Papan. class	36.05

Sample S006 | Specific diagnosis



Specific diagnosis	n
Atypical glandular cells of undetermined significance, AGC-NOS	8
Atypical glandular cells, favour neoplastic, AGC-FN	12
Atypical glandular endocervical cells of undetermined significance, AGC-NOS	3
Atypical glandular endocervical cells, favour neoplastic, AGC-FN	3
Atypical glandular endometrial cells of undetermined significance, AGC-NOS	21
Atypical glandular endometrial cells, favour neoplastic, AGC-FN	39
Atypical squamous cells, cannot exclude HSIL, ASC-H	5
Benign endometrium	1
Endometrial adenocarcinoma	38
Extrauterine adenocarcinoma	1
Fungal organism	1
High grade SIL (CIN2, moderate dysplasia, CIN3, severe dysplasia, CIS)	3
Negative for intraepithelial lesion and malignancy, NILM	3

Agreement percentage of the responses	%
The most common diagnosis	28.26

Negative for intraepithelial lesion and malignancy, NILM	3
Total	138

Clinical cytology, virtual microscopy Gynaecological cytology (liquid) Round 1, 2022

2022-11-15

REVISED FINAL REPORT

Product no. 6701

Subcontracting: Sample preparation,
Digital image services

Samples sent	2022-07-05
Round closed	2022-08-23
Final report	2022-11-07

Request for correction

Typing errors in laboratory's result forms are on laboratory's responsibility. Labquality accepts responsibility only for result processing. Requests must be notified by writing within three weeks from the date of this letter.

Authorized by

EQA Coordinator
Pia Eloranta
pia.eloranta@labquality.fi

Expert

Docent Pekka Laurila, MD, PhD,
Department of pathology
HUSLAB, Helsinki University Central
Hospital
Helsinki, Finland

Labquality Oy

Kumpulantie 15
FI-00520 HELSINKI
Finland

Tel. + 358 9 8566 8200
Fax + 358 9 8566 8280

info@labquality.fi
www.labquality.fi



This Report replaces: Final Report, Clinical cytology, virtual microscopy Gynaecological cytology (liquid) Round 1, 2022, 7th of November 2022.

Reason for the amendment: Error in comments in case S003. No impact on customer reports.

Amendment: Corrected case S003 comment: "The histological changes were consistent with HPV infection and LSIL"

Specimens

Sample S001 – S005 (LQ779522011 – LQ779522016) were gynaecological, Papanicolaou stained cytology liquid-based cytology samples virtual microscopy images. The slides were chosen from routine material of a pathology laboratory. Age of the patient and information about point of menstrual cycle, hormone therapy, contraception and clinical history were given when available. The samples were available only as virtual images on this round.

Report info

The final report contains distribution of diagnoses and diagnostic agreement. Laboratory's own result is marked with a black radio button (Ⓞ). Common instruction guidelines how to interpret the reports can be found under "LabScala user instructions" in LabScala.

It is important to take into account that this external quality assurance scheme does not evaluate cytological examination as a medical consultation. It is intended for interlaboratory comparison including features that may vary between respondents. In case you have any questions regarding the reports, please contact the EQA coordinator

Comments – Expert

S001: Female 54 yr. 2017 a solid tumorlike process ca 6.5 cm, was detected in the uterine corpus. No symptoms. Annual cytology controls recommended. Now a control LBC sample.

Mainly normal ectocervical squamous cells were seen in the LBC sample. The sample consisted mainly of mature superficial squamous cells. Minimal nuclear variation was observed. No diagnostic changes were seen.

Cytological diagnosis: NILM, negative for intraepithelial lesion or malignancy
Papanicolaou class: I

HPV-HR test was negative. Histologically no signs of squamous intraepithelial lesions were detected. The most common diagnosis made by the respondents was NILM (60.3%). The most common Papanicolaou class was Class 1 (51.65 %). The share of classes 0-2 was 73%. The overall agreement of the diagnoses made by the respondents was good.

S002: Female 62 years. Previously treated for squamous cell carcinoma of the skin. Recently an abnormal ultrasound sonography of the uterine corpus. No uterine discharge. An LBC sample was taken. Any signs of malignancy?

Cytologically a background of atrophic squamous cells and relatively abundant inflammatory cells was seen. Some cell groups contained markedly abnormal, columnar epithelial cells with enlarged nuclei with increased variation of nuclear size. The cells were hyperchromatic with relatively large cytoplasm. Occasional glandular structures could be discerned.

Cytological diagnosis: AGC-FN, atypical glandular cells, favor neoplasia, endometrial
Papanicolaou class: IV

The histological sample showed an endometrial adenocarcinoma, clear cell carcinoma. The most common diagnosis given by the respondents was ASC-H (20.85%). The second most common diagnosis was AGC-NOS (15.1%). The most common Papanicolaou class was Class V (52.1%). The second most common Papanicolaou class was class IV (42.22%). The share of classes III-V was 91%. The overall agreement of the diagnoses made by the respondents was moderate.

S003: Female, 66 years. Several years prior hysterectomy due to uterine prolapse. Previously HPV-positive. Now a control LBC sample from the vagina.

The cytological sample showed mostly normal superficial and intermediate squamous cells. Several cell groups showed somewhat increased nuclear size with slightly irregular nuclear membrane. Some binucleate cells were seen. The changes were suggestive of HPV infection and the cytological diagnosis ASCUS was made.

Cytological diagnosis: ASCUS, Atypical squamous cells of undetermined significance (LSIL also acceptable)
Papanicolaou class: II (Class III also acceptable)

The vaginal biopsy showed slightly hyperplastic and parakeratotic squamous epithelium. The histological changes were consistent with HPV infection and LSIL. The most common diagnosis made by the respondents was LSIL (48.92%). The second most common diagnosis was ASCUS (39.5%). The most common Papanicolaou class was Class III (57.47%). The overall agreement of the diagnoses made by the respondents was good.

S004: Female, 43 years. 2 years prior LEEP-cone due to LSIL. Postoperatively HPV positive. Now colposcopy was performed and no acetowhite staining of epithelium was observed. LBC sample was taken.

Cytologically normal ectocervical squamous cells were seen in the background. In addition, some groups of cells with larger hyperchromatic nuclei and irregular nuclear membrane were seen. Perinuclear cytoplasmic halo consistent with koilocytosis was seen in the squamous epithelial cells. The finding was consistent with HPV infection. The cytological diagnosis was LSIL.

Cytological diagnosis Low-grade squamous intraepithelial lesion (LSIL)
Papanicolaou class: III

The histological sample showed changes consistent with low-grade squamous intraepithelial lesion (LSIL) and HPV infection. Histologically CIN1-type of lesion. The most common diagnosis given by the respondents was LSIL (41.01%). The second most common diagnoses were HSIL (30.2%). The most common Papanicolaou class was Class IV (44.19%). The overall agreement of the diagnoses made by the respondents was good.

S005: Female 59 years old. Uterine discharge was observed. LBC sample from the uterine cervix.

Cytologically a relatively abundant sample was seen. An abnormal finding consisting of single and groups of atypical squamous cells epithelial cells. The cells contained large and hyperchromatic nuclei with some prominent nucleoli. Some dyskeratotic cells were observed. The nuclei were large and hyperchromatic, nuclear-cytoplasmic ratio was increased. Necrotic debris and inflammatory reaction consistent with tumor diathesis, were seen in the background. The cytological changes are consistent squamous cell carcinoma or suspicion of squamous cell carcinoma.

Cytological diagnosis: Squamous cell carcinoma, or suspicion.
Papanicolaou class: IV (also class V acceptable).

The histological sample showed an invasive squamous cell carcinoma with positive HPV markers. The finding was consistent with HPV-associated squamous cell carcinoma. The most common diagnosis given by the respondents was squamous cell carcinoma or suspicion (73%). The second most common diagnosis was HSIL (19%). The most common Papanicolaou class was Class V (76.7%). The share of classes III-V was 96.5%. The overall agreement of the diagnoses made by the respondents was very good.

S006: Female, 79 years. Postmenopausal bleeding. Uterine ultrasound was abnormal. LBC sample was taken.

The cytological sample showed numerous normal squamous cells in the background. Among the squamous cells some groups of smaller columnar epithelial cells were observed. These cells had larger hyperchromatic nuclei, somewhat irregular nuclear membrane and hyperchromasia. The finding is consistent with high-grade glandular cell atypia suspicious for neoplasia, primarily endometrial atypical glandular cells.

Cytological diagnosis: AGC-FN, atypical glandular cells endometrial, favor neoplasia
Papanicolaou class: IV

The histological sample showed low-grade endometrioid carcinoma of endometrium. The most common diagnosis given by the respondents was AGC-FN, endometrial (28.2%). The second most common diagnosis was endometrial adenocarcinoma (27.5%). The most common Papanicolaou class was Class V (36.0%). The second most common Papanicolaou class was class IV (31.4%). The share of classes III-V was 91%. The overall agreement of the diagnoses made by the respondents was very good.

End of report

Copyright © Labquality Oy

Labquality does not permit any reproduction for commercial purposes of any portion of the material subject to this copyright. Labquality prohibits any use of its name, or reference to Labquality EQA program, or material in this report in any advertising, brochures or other commercial publications. Labquality EQA data do not necessarily indicate the superiority of instruments, reagents, testing equipments or materials used by participating laboratories. Use of Labquality EQA data to suggest superiority or inferiority of equipments or materials may be deceptive and misleading. Proficiency test results are handled confidentially. Labquality will not issue any statements to third parties of the performance of laboratories in external quality assessment schemes unless otherwise agreed.